

Role of 3-Dimensional Sonohysterography in Infertility

Dr. Asha Verma¹, Dr. Anil Gurjar², Dr. Purna Soniya³, Dr. Richa Gupta⁴,
Dr. Disha Gupta⁵

¹Professor, Department of Obstetrics and Gynaecology, SMS Medical College, Jaipur (Rajasthan) India.

²Assistant Professor, Department of Obstetrics and Gynaecology, SMS Medical College, Jaipur (Rajasthan) India

^{3,5}Junior Resident, Department of Obstetrics and Gynaecology, SMS Medical College, Jaipur (Rajasthan) India

⁵Senior Resident, Department of Obstetrics and Gynaecology, AIIMS, Jodhpur (Rajasthan) India

Abstract—3D ultrasound (3-dimensional sonography) when combined with sonosalpingography, it provides detailed information regarding internal and external contours of the uterus, without the need for radiation contrast material or surgical intervention. This study was done because of the need of such diagnostic modality that is highly accurate as well as least invasive. A descriptive study was conducted on 50 infertile females to assess the diagnostic value of 3-dimensional SHG in reference of diagnostic hystero-laproscopy (DHL) assuming as gold standard. It was found that sensitivity of 3-dimensional SHG reasons of tubal patency, ovarian pathology and uterine cavity was found 97.6%, 90.91% and 71.43% respectively. And diagnostic accuracy of 3-dimensional SHG in reference of DHL for tubal patency, ovarian pathology and for uterine cavity was found 96%, 92% and 96% respectively. So it can be concluded from present study that 3-Dimensional sonohysterography is an efficient tool to assess women with infertility. Its sensitivity, specificity, and diagnostic accuracy is comparable to hysteroscopy.

Keywords: Infertility, 3-dimensional SHG (SHG), Diagnostic Hystero-Laproscopy (DHL), Diagnostic Values.

I. INTRODUCTION

Infertility is defined by WHO as “inability to conceive after 12 months or more of regular unprotected intercourse by a couple in reproductive age group.”¹ It is classified as Primary infertility where no previous pregnancy has occurred and Secondary infertility where at least one pregnancy has taken place irrespective of outcome. Causes of infertility are male factors (30-40%), tubal and peritoneal pathology (30-40%), ovulatory dysfunction (20-40%) and Unexplained factors.

Factors responsible for female infertility are (1) Ovarian factors which includes polycystic ovarian disease, anovulation, diminished ovarian reserve, luteal dysfunction, premature ovarian failure, gonadal dysgenesis. (2) Tubal and peritoneal factors including pelvic inflammatory disease and tubal occlusion (3) Uterine factors including uterine malinormations, uterine fibroid, Asherman's syndrome, endometriosis, inadequate secretory endometrium, endometrial polyps.

Although evaluation for infertility should be offered to all couples who fails to conceive after one year or more of regular unprotected intercourse, but its not mandatory it can be started earlier in certain circumstances. Earlier evaluation is justified for women with irregular mensus, history of pelvic infection or having a male with known or suspected poor semen quality and is also warranted after 6 months of unsuccessful effort by the women over the age of 35 years.²

The basic methods for evaluation of uterine cavity and tubal patency are Hysterosalpingography, Transvaginal sonography, Saline sonosalpingography, Hysteroscopy, Laproscopy and 3D ultrasound with saline salpingography.

3D ultrasound (3-dimensional sonography) when combined with sonosalpingography, it provides detailed information regarding internal and external contours of the uterus, without the need for radiation contrast material or surgical intervention.

This study was done because of the need of such diagnostic modality that is highly accurate as well as least invasive.

II. METHODOLOGY

A hospital based descriptive type of study was conducted on 50 infertile couples attending at department of Obstetrics and Gynaecology attached to SMS Medical College, Jaipur (Rajasthan) India from October 2015 to January 2017.

Sample size was calculated 34 subjects assuming 92% sensitivity of 3 dimensional sonohysterography at 95% confidence limit and relative allowable error of 10%. Assuming 12% drop out rate, the sample size came out to be 41 which was then rounded off to 50 patients.

For the study purpose all infertile females with normal pelvic bimanual examination and normal transvaginal sonography attending at department of Obstetrics and Gynaecology attached to SMS Medical College, Jaipur, were included in this study. Before going to proceed further written informed consent was taken from all participants. Out of that females having active pelvic inflammatory disease and known for contraindication for anaesthesia were excluded from study. Finally 50 eligible infertile females were included in this study.

Preliminary work and investigations: It includes detailed history of eligible infertile females regarding demographic profile, infertility profile (whether primary secondary or duration of infertility), menstrual cycle, obstetric history, past history and personal history. General physical and systemic examinations were also done of these females. Then these females were evaluated as per various investigations which includes routine investigations, X ray chest, ECG, Transvaginal ultrasound, Hormonal assay such as Serum T3, T4, TSH, Serum Prolactin.

Diagnostic modalities used for evaluation of infertility in this study are:(1) 3-dimensional ultrasound with sonohysterography, (2) Diagnostic hysteroscopy and (3)Diagnostic laproscopy.

All the procedures were performed in postmenstrual phase of the menstrual cycle as endometrium is thin and provides better visualization of endometrial cavity. Also it avoids possibility of disrupting an early pregnancy.^{3,4}

Sonosalingography was performed by a single operator using 3 dimensional ultrasound system with 5MHz transvaginal transducer between days 5 and 10 of menstrual cycle. The woman was placed in lithotomy position. A sterile vaginal speculum was inserted. A Foleys catheter size no.8 was placed just above the internal os and the balloon was inflated with 1 to 2 ml of sterile saline solution for stabilization and occlusion of internal os. The ballon of the cathetor was inflated with the minimal amount of saline solution that stabilized it. Then a 20ml plastic syringe (containing solution of ciprofloxacin and hyaluronidase with dexamethasone) was attached to it. The transducer was gently introduced into the posterior vaginal fornix and the solution was slowly introduced into the uterus while uterine distention was monitored. Around 5-15ml of fluid was required for distention. At this stage, architecture of the uterine cavity was observed using 3D-SHG.Examination was performed in 2

perpendicular planes, both sagittal and transverse, scanning from cornua to cornua. Uterine lesions including site, size, echogenicity and relation to uterine cavity were visualized.

While the fluid was being pushed into the uterine cavity bilateral ovaries were focused to look for fountain effect on color doppler. Again fluid in the pouch of douglas was looked for as it gives an idea about tubal patency irrespective of laterality.

The endovaginal probe was slowly withdrawn and the catheter was removed. The patients were then subjected to diagnostic hysterolaproscopy, the following day. All hysterolaprosopies were done by the same operator to avoid interobserver variations.

All the findings were recorded along with other general information previously collected. Data thus obtained were compiled in MS Excel 2010 worksheet. Frequencies were expressed in proportions.

III. RESULTS

The present study was conducted to assess the role of 3-dimensional sonosalpingography as a diagnostic modality in infertility work up in comparison to diagnostic hysterolaproscopy. Total 50 infertile women were included in the study.

Out of 50 infertile women, majority i.e.31 (62%) were of primary infertility and 19(38%) were of secondary infertility. The mean age of cases of infertility in the study population was 26.58_±4.19 years and mean duration of infertility was 4.33_±3.06 years. (Table 1)

Out of 50 cases of Infertility both 3d SHG and DHL revealed bilateral patency in 42(84%) cases and blockage in 8(16%) cases.(Table 1)

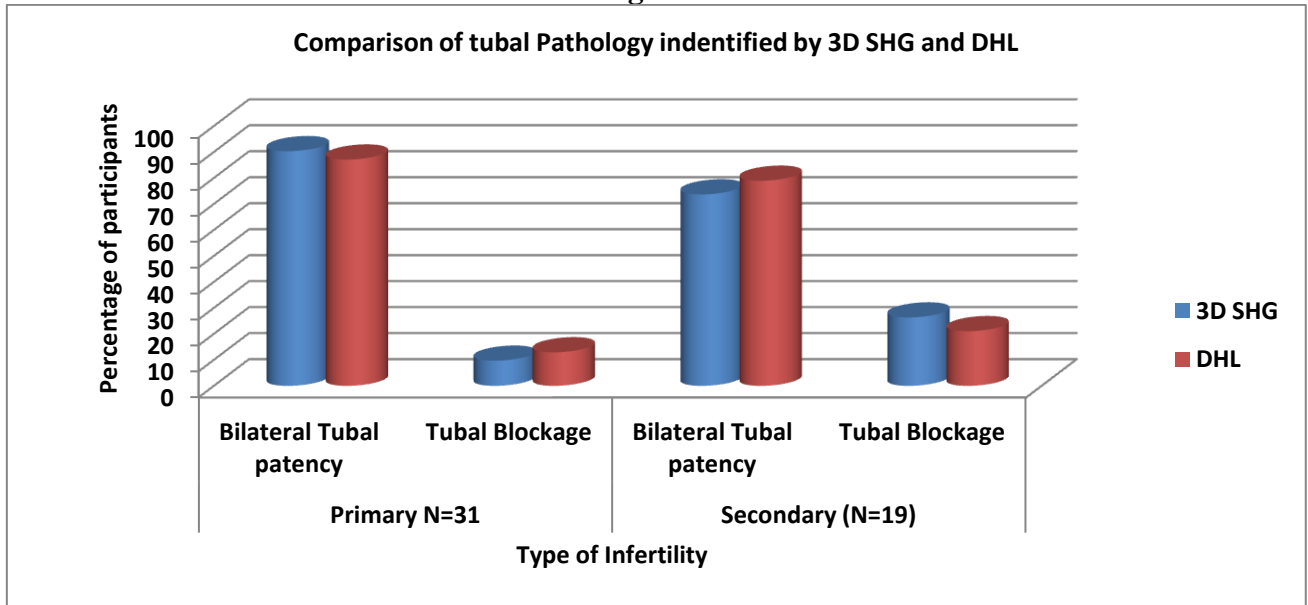
Table 1
Comparison of tubal pathology identified between 3D SHG and DHL

Type of Infertility	Investigating Method	Bilateral Tubal Patency N0 (%)	Tubal Blockage N0 (%)	P value
Primary N=31	3D SHG	28 (90.32)	3 (9.68)	>0.05
	DHL	27 (87.1)	4 (12.9)	
Secondary (N=19)	3D SHG	14 (73.68)	5 (26.32)	>0.05
	DHL	15 (78.95)	4 (21.05)	
Total (N=50)	3D SHG	42 (84)	8 (16)	>0.05
	DHL	42 (84)	8 (16)	

Out of 31 cases of primary infertility,3-dimensional sonosalpingography revealed bilateral tubal patency in 28 (90.32%) cases and blockage either unilateral or bilateral in 3(9.68%) cases and laprosopy revealed bilateral tubal patency in 27(87.1%) cases and blockage either unilateral or bilateral in 4(12.9%). (Table1& Figure 1)

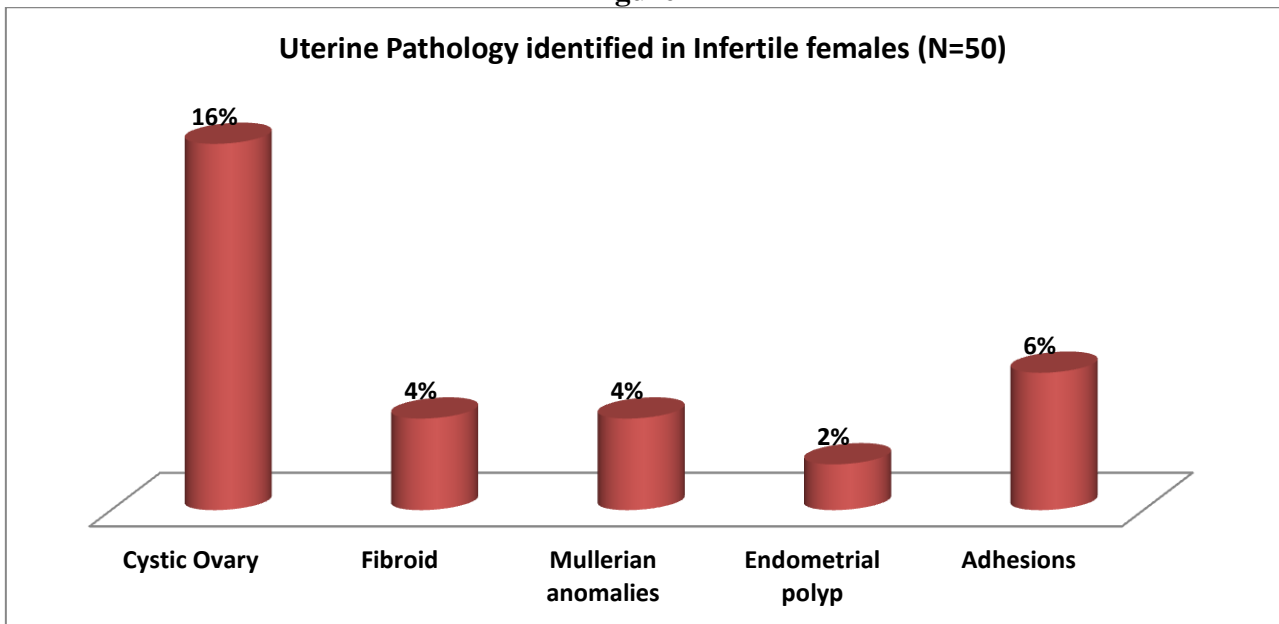
Out of 19 cases of secondary infertility,3-dimensional sonosalpingography revealed bilateral patency in 14(73.68%) cases and block in 5(26.32%) and laprosopy revealed bilateral patency in 15 (78.95%) cases and blockage in 4(21.05%)cases. (Table1& Figure 1)

Figure 1



3-dimensional SHG picked up additional findings like cystic ovary in 8(16%)cases, fibroid in 2(4%)cases, 2(4%) cases of mullerian anomalies and 1(2%) case of endometrial polyp. The most important additional finding picked up by laparoscopy was adhesions which was seen in 3(6%)cases. (Figure 2)

Figure 2



When diagnostic values of tubal patency of 3-dimensional SHG was analysed in reference of assuming findings of diagnostic hystero-laproscopy (DHL) on these women. It was found that it was able to pick 97.6% of cases but wrongly diagnosed were 12.5% cases, so accuracy of diagnostic values of tubal patency of 3-dimensional SHG in reference DHL was found 96%. For ovarian pathology, this accuracy was 92% and for uterine cavity it was found 96%. (Table 2)

Table 2
Comparison of diagnostic values of 3-dimensional Sonosalpingography assuming Diagnostic Hysteroscopy as Gold Standard

Diagnostic values	Tubal Patency	Ovarian Pathology	Uterine Cavity
Sensitivity	97.60	90.91	71.43
Specificity	87.50	92.31	100.00
Positive Predictive Value	97.60	79.92	100.00
Negative Predictive Value	87.50	97.30	95.56
Accuracy	96.00	92.00	96.00

IV. DISCUSSION

In this study, 84% of infertile women had bilateral tubal patency while blockage either unilateral or bilateral was found in 16%. Authors had find that even with a complete work up, the reason for infertility is not always obvious;5-15% of infertile couples have a normal results of every clinical tests.^{5,6}

Present study also observed cystic ovary in 16%, fibroid in 4%, mullerian anomalies in 4%, 2% endometrial polyp and adhesions was found in 6% in these infertile women. Structural abnormalities of the uterus, endometrial cavity and tubal patency may adversely affect reproductive outcome by interfering with implantation, causing infertility.⁷ Among the various causes tubal and peritoneal pathology accounts for 30-35% infertile couples⁸

Screening for uterine abnormalities is a part of routine clinical investigations of women with history of infertility, recurrent miscarriages and preterm labor.⁹ Current imaging techniques for evaluating the uterus, uterine cavity and endometrium include transvaginal ultrasound (TVUS), hysterosalpingography (HSG), sonohysterography(SHG), hysteroscopy, laparoscopy and magnetic resonance imaging.

It was also revealed in this study that sensitivity of 3-dimensional SHG reasons of tubal patency, ovarian pathology and uterine cavity was found 97.6%, 90.91% and 71.43% respectively. And diagnostic accuracy of 3-dimensional SHG in reference of DHL for tubal patency, ovarian pathology and for uterine cavity was found 96%, 92% and 96% respectively. Transvaginal ultrasound is increasingly being used as a first line of investigations in patients with endometrial abnormalities.¹⁰ 3-dimensional ultrasound is a new imaging technique with ability to register the 3 planes that are not visible in 2-dimensional ultrasonography, enabling visualization of the uterus and endometrial cavity from any chosen angle and in any arbitrary plane.¹¹ Three dimensional Ultrasound has become a key tool for diagnosing uterine malformations. In case of septate uterus, the accuracy of diagnosing is 98%.¹² It also facilitates noninvasive evaluation of the uterine endometrium and identifies some organic problems that can negatively influence the implantation process.^{13,14}

Lasmar RB et al (2010)¹⁵ described hysteroscopic findings in infertile females. They concluded that intrauterine synechiae were most frequent abnormal findings in patients evaluated for infertility. Bingol B et al(2011)¹⁶ compared the accuracy of transvaginal sonography(TVS),saline infusion sonohysterography(SIS) and hysteroscopy(HS) for uterine pathologies among infertile women.SIS showed a sensitivity of 87%,specificity of 100% and PPV of 100% for endometrial hyperplasia. Hysteroscopy had a sensitivity, specificity, PPV,and NPV of 98%,83%,96% and 91% respectively for overall uterine pathologies. Finally SIS seems to be superior to TVS, for uterine pathologies with respect to hysteroscopy as the gold standard. Viela JR(2012)¹⁷ compared the diagnostic accuracy of

sonohysterography and conventional TVS in assessing uterine cavity of infertile women candidate to ART. They concluded that SHG was more accurate than USG in assessment of uterine cavity of infertile female candidate to ART. SHG can be easily incorporated into investigation of these females, thus reducing embryo implantation failure. Yenigul NN(2016)¹⁸ conducted a study on 24 patients and concluded that 3-D SHG took significantly less time and induced less patient discomfort than did vaginoscopic hysteroscopy(VH). They suggested that 3-D SHG should be the first choice for outpatient evaluation of uterine cavity in patients of infertility.

V. CONCLUSION

It can be concluded from present study that 3-Dimensional sonohysterography is a practical, easily accessible, acceptable, non-invasive and efficient tool to assess women with infertility. Its sensitivity, specificity, and diagnostic accuracy is comparable to hysteroscopy, which is gold standard for evaluation of infertile women. But the later is invasive, requires operative skill and has inherent risk of surgery and anaesthesia. Thus in the hands of skilled practitioner with a good technological basis, 3-dimensional sonohysterography can replace the invasive methods, as a preliminary diagnostic tool, in infertility work up and endoscopies reserved for women with abnormal findings in 3DSHG, requiring therapeutic intervention

CONFLICT OF INTEREST

None declared till now.

REFERENCES

- [1] Vayena E, Rose PJ and Griffin PD(eds). World Health Organization(2001). Who Infertility Glossary, in current practises and controversies in Assisted Reproduction. Report of a meeting on "Medical, Ethical and Social Aspects of Assisted Reproduction" WHO Headquarter. Geneva, Switzerland
- [2] Marc A Fritz, Leon Speroff. Clinical Gynaecologic Endocrinologic and Infertility, Lippincott Williams & Wilkins, 8th edition, chapter 27, 1156-1158
- [3] Carol M Rumack, Stephanie R Wilson, J William Charboneau. Diagnostic Ultrasound 3rd edition, Elsevier Books, Chapter 15, P.529-549
- [4] Wolman, Groutz A, Gordon D, Kupferminc MJ, Lessing JB, Jaffa AJ. Timing of sonohysterography in menstruating women. Gynecol Obstet Invest, 1999;48(4):254-8
- [5] Adamson GD, Baker VL. Subfertility: causes, treatment and outcome. Best Pract Res Clin Obstet Gynecol 2003;17:169-185
- [6] de boer EJ, den Tonkelaer I, Burger CW, Van Leeuwen FE. Validity of self reported causes of subfertility. Am J Epidemiol, 2005;16:978-986.
- [7] Kim AH, Mc Kay H, Keltz MD, Nelson HL, Aamson GD. Sonohysterographic screening before in vitro fertilization. Fertil Sterile, 1998;96:814-844.
- [8] Miller JH, Weinberg RK, Canino NL, Klein NA, Soules MR. The pattern of infertility diagnosis in women of advanced reproductive age. Am J Obstet Gynecol, 1999;181:952-7.
- [9] Rai R, Clifford K, Regan L. The modern preventative treatment of recurrent miscarriage. Br J Obstet Gynaecol, 1996;103(2):106-110.
- [10] Dij Khuzen FPHLJ, Brolman HAM, Potters AE, Bongers MY, Heints APM. The accuracy of transvaginal ultrasonography in the diagnosis of endometrial abnormalities. Obstet Gynaecol, 1996;87:345-349.
- [11] American college of Obstetricians and Gynaecologists. ACOG Technology Assessment in Obstetrics and Gynaecology. No.5: Sonohysterography. Obstet Gynaecol, 2008;112:1467-1469.
- [12] Kupesic S. Three dimensional ultrasound in reproductive medicine. Ultrasound Rev Obstet Gynecol, 2005;5:304-15
- [13] Nargund G. Time for an ultrasound revolution in reproductive medicine. Ultrasound Obstet Gynecol, 2005;20:107-11.
- [14] Lindhard A, Ravn V, Bentin-Ley U, et al. Ultrasound characteristics and histological dating of the endometrium in a natural cycle in infertile women compared with fertile controls. Fertil Steril, 2006;86:1344-55.

-
- [15] Lasmar RB, Barrozo PR, Parente RC, Lasmar BP, da Rosa DB, Penna IA, Dias R. Hysteroscopic evaluation in patients with infertility. *Rev Bras Ginecol Obstet*,2010Aug;32(8):393-7.
- [16] Bingol B, Gunenc Z, Gedikbasi A, Guner H, Tasdemir S, Tiras B. Comparison of diagnostic accuracy of saline infusionsonohysterography, transvaginal sonography and hysteroscopy in postmenopausal bleeding. *J Obstet Gynaecol* , 2011;31(1):54-8.
- [17] Vilela JR, Cardoso MT, Franco Junior JG, Pontes A. Sonohysterography accuracy versus transvaginal ultrasound in infertile women candidate to assisted reproduction techniques. *Rev Bras Ginecol Obstet*,2012 Mar;34(3):122-7
- [18] Nefise Nazli Yenigul,Cicek O. The role of three-dimensional ultrasonography in female infertility. *Clinics Mother Child Health*,2016;13:236.