

Button cell battery as foreign body ingestion in children: A retrospective analysis in a tertiary care center

Dr. Vikrant Kumar Sharma¹, Dr. Manish Kumar Tailor^{2§}, Dr. Digvijay Singh Rawat³,
Dr. P. C. Verma⁴, Dr. Yogesh Aseri⁵, Dr. B K Singh⁶

¹Junior Resident, Department of Otorhinolaryngology, JLN Medical College, Ajmer (Rajasthan) India.

²Senior Specialist, Department of Otorhinolaryngology, JLN Medical College, Ajmer (Rajasthan) India

^{3,5}Assistant Professor, Department of Otorhinolaryngology, JLN Medical College, Ajmer (Rajasthan) India

^{4,6}Senior Professor, Department of Otorhinolaryngology, JLN Medical College, Ajmer (Rajasthan) India

[§]Corresponding author's Email: manishtailor.tailor@gmail.com

Abstract—*Button cell foreign bodies are increasingly presented as foreign bodies in esophagus. Many a time no positive id on button cell and can be mistaken as foreign body coin and delayed for management. Retrospectively analyze of 19 admitted cases with foreign body ingestion in children for foreign body Lithium ion battery button cell in esophagus done with the aim to evaluate epidemiology, clinical presentation and duration of presentation, radiological findings, endoscopic findings and complications in such cases. Clinical record of patients with foreign body Button cell batteries was reviewed and compiled in Microsoft Excel sheet and descriptive and percentage analysis was done. There were 11 (57.89%) male patients and 8 female patients. History of foreign body battery cell was given by the parents of 10 children. 3 patients presented with respiratory complains. After history and radiological examination in 17 out of 19 patients presence of lithium cell battery was suspected prior to endoscopic removal. In 4 patients severe mucosal injury noted. It was concluded from this study that foreign body button cell can cause serious injuries to upper aerodigestive tract. These should be promptly removed.*

Keywords: *Foreign bodies, Button battery, Halo sign, Double rim sign.*

I. INTRODUCTION

The natural curiosity of children leads them to ingest many types of non-edible objects. Mostly swallow foreign bodies are accidental but sometimes individuals ingest, coins, pencil tips, metallic foreign bodies, battery cells (lithium) and while meat bone (chicken bone/fish bone/mutton/buff) are common in adults and elderly.¹⁻³ The majority of foreign objects ingestions occur in between six months and six years of age while in adults true foreign object ingestion commonly occurs among those with psychiatric disorders, mental retardation or impairment caused by alcohol and old age.² Foreign bodies frequently lodge in the cricopharyngeal and oesophageal regions because off point of natural narrowing at 15 and 25 centimetres, but impaction at these level may have more to do with motility patterns than anatomy.¹⁻³ All blunt or sharp foreign bodies should be considered as an emergency to reduce the associated complications. If not removed on time, it can cause intramural mucosal injury, perforation, subacute mediastinitis, aortoesophageal fistula, tracheoesophageal fistula, and long-term residual injury to the esophagus.⁴

The lithium battery cells are increase morbidity as they causes early mucosal damage, and may lead to life-threatening complications in long-standing cases.^{3,4} Swallowed coin-size lithium batteries become lodged in the upper esophagus and react quickly with saliva. The battery discharges a current that hydrolyzes water and generates hydroxide, creating a caustic injury to the tissue. Therefore, removal of these should be accorded highest priority to prevent complications.^{3,5,6} We wish to present, in this

paper, our experience of treating such foreign bodies last three year period.

II. METHODOLOGY

This study was conducted in the Department of Otorhinolaryngology and Head Neck Surgery at J L N Medical College and Hospital, Ajmer, Rajasthan. The tertiary care institute is a state run Medical College Hospital, and serves the population of 5 districts. The Government of Rajasthan is providing completely free routine and emergency healthcare to all. The Department of Otorhinolaryngology and Head Neck Surgery at JLN Medical College, Ajmer is well equipped having Karl Storz™ rigid and flexible endoscopes with recording and reporting hardware and Capture IT proHD™ software.

A retrospective analysis of 19 cases of lithium battery cells foreign body ingestion were done in patients admitted in the Department of Otorhinolaryngology and Head Neck Surgery of Jawahar Lal Nehru Medical College and Hospital, Ajmer in between January 2012 and June 2016. All age groups with lithium battery foreign bodies were included. Patients' records were reviewed for demographics, clinical presentations, duration of foreign body impaction, location of foreign body, rigid endoscopic removal.

III. RESULT

During the study period a total of 146 rigid esophagoscopies were performed to find out foreign bodies in esophagus in the Department of ENT, JLN Medical College and Hospital Ajmer. The most common foreign body was coin at the level of cricopharynx in 110 cases followed by button cell batteries in 19 cases, meat bolus in 8 cases, denture in 5 cases, and vegetative foreign bodies in 4 cases (Seed of Jamun/bare/ whole lime). (Figure 1)

Figure 1

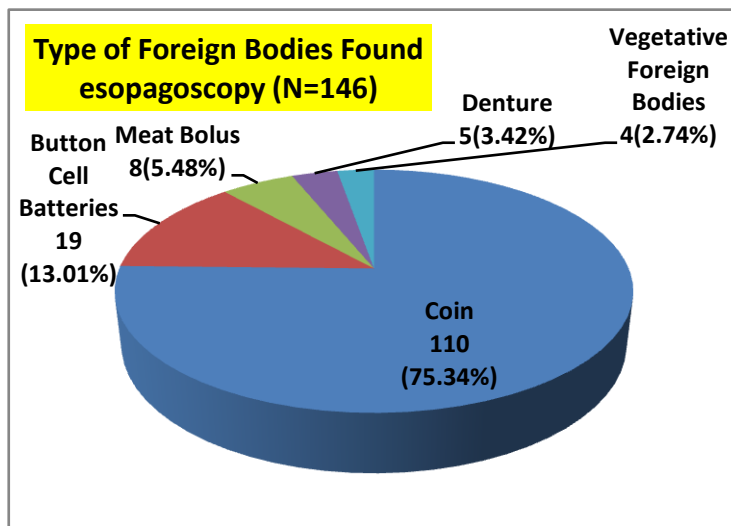
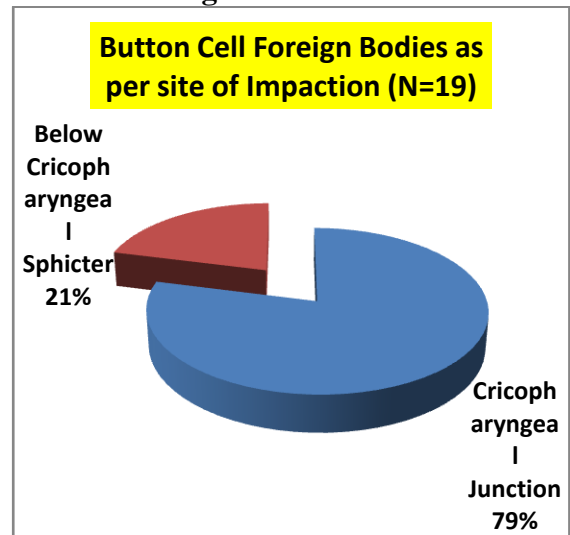


Figure 2



There were 19 cases of foreign body battery cell ingestion. There were 11 (57.89%) male patients while female patients were 8 (42.10%). The male to female ratio was 1.4:1. Out of which 13 (68.41%) were 1-4 years and 6 (31.57%) above 4 year children. Foreign bodies were common in 1-4 year age group in children. (Table 1)

History of foreign body battery cell was given by the parents of 10 children. Chief complains were ingestion of foreign body battery by parents, inability to swallow, and vomiting of ingested food. 3 patients presented with respiratory symptoms. Patient presented to us after 4 hrs to 7days after ingestion

of lithium cell batteries. (Table 1)

Table 1
Characteristics of Study participants

Variables		Number	Percentage (%)
Sex	Male	11	57.89
	Female	8	42.10
Age	1-4 Years	13	68.41
	>4 Years	6	31.57
H/o Ingestion of Foreign Body	Yes	10	52.63
	No	9	47.37
Symptoms related	GIT	19	100
	Respiratory	3	15.78

16 patients have consulted in emergency Department, physician/ pediatrician and referred to Department of ENT, only 3 patient directly presented in Department of ENT. All 16 patients referred presented with X-ray Chest including neck but the provisional diagnosis was foreign body probably a coin in 9 patients. Out of those 16 patients, 7 were referred from emergency with the instruction to keep the patient nil per oral. However rest all patients presented to us was not aware of keeping the kid fasting. X-ray Chest including neck and abdomen was done in each case. After history and radiological examination in 17 out of 19 patients presence of lithium cell battery was suspected prior to endoscopic removal. In 2 patients presence of foreign body battery was detected during rigid endoscopic removal.

The location of the impaction differed, the most common site of all these foreign bodies was at cricopharyngeal junction 15 (78.94%) while below cricopharyngeal sphincter at the mid esophagus level in mediastinum roughly corresponding to second and third constriction in 4 (21.05%) patients. (Figure 2)

In all patients rigid oesophagoscopy under general anesthesia were done to remove foreign bodies. On inspection, impacted site had stain of chemicals and mucosal injury. Edema and sever mucosal injury was noted in 4 patients. In those 4 infant feeding tube inserted under direct supervision. On inspection, the foreign body was found to be discolored, with corrosion of one surface. There was no mortality noted during entire period of this study.

The children were observed for immediate complications like dysphagia, odynophagia, mucosa erosion, ulcer, infection, local mucosa edema, mucositis causing stridor and aspiration in cases of delayed intervention. Nasogastric tube/oral feeding was initiated after 6 hours. Antibiotics, steroids and anti-inflammatory drugs were given as a 7-day course. The toddler recovered uneventfully in the immediate post-operative period.

IV. DISCUSSION

After nose and ear, cricopharynx is the commonest site for foreign body impaction.² Lithium cells are a common power source for household products and electronic toys. Lithium cells usually disposable, anode materials are zinc or lithium and cathode materials are manganese dioxide, silver oxide, cupric oxide. Mucosal injury due to lithium cell batteries may be due to leakage of corrosive content, electrical current and pressure necrosis.^{7,8}

The damage is caused, not by the contents of the battery, but by the electric current it creates. Unlike other button batteries, lithium coin cells contain a mildly irritating organic electrolyte instead of an

alkaline electrolyte; therefore, leakage does not cause the local injury. Furthermore, 20-mm lithium cells are 3-V cells (twice the 1.5 V of other button cells), have a higher capacitance, and generate more current; therefore, lithium cells generate more hydroxide, more rapidly, than other button cells.^{7,8} Long time impaction of a foreign body in the esophagus causes edema of the mucosa, and the esophageal wall becomes weakened. Retention leads to perforation, which is only a matter of time.⁴ Therefore, all foreign bodies retained in the esophagus should be removed as soon as diagnosed.⁷ Delay in removal of lithium battery cells cause leaking of chemicals, mucosal injury due to liquefaction necrosis of mucosa, esophageal perforation and chance of stricture.²

In a study by Litovitz et al., 8648 battery ingestions cases reported, who were younger than 6 years.⁹ In the Taipei Veterans General Hospital Poison Control Center, of 25 patients with button battery ingestion, Button battery ingestion occurred most commonly in male children (N=20; 80%) and children under 3 years of age (N= 19; 76%).¹⁰ The results of the above studies suggest that majority of the patients with ingested foreign bodies in esophagus are children. This can be explained by the explorative nature of the children.

There were 57.89% male and 42.10% female patients in our study and the male to female ratio was 1.4:1. Most of the studies confirm that foreign bodies are common among males.^{1,3}

According to present study, button batteries are more likely to become lodged at cricopharynx in younger children because of the narrowing of lumen. Most of these batteries involved are large ones, i.e. 20 mm or more of diameter. They obviously find difficult going through cricopharynx. Natural esophageal narrowing explains the reason of batteries remain at different sites. mostly in the upper portion: cricopharynx, aortic arc and the initial portion of left bronchus make lumen diameter slightly narrow physiologically and therefore, a foreign body is prone to remain at this level.^{1,3}

Mostly children with foreign body button cell ingestion are asymptomatic and without complications. Although dysphagia and odynophagia are very common in these patients, are due to mucosal edema.^{3,7} They are non-specific symptoms might hinder diagnosis in cases where the battery ingestion was unnoticed. This could be the reason delay in diagnosis.⁵

The diagnosis of esophageal battery cell impaction is usually made on the basis of medical history and clinical manifestations. But imaging studies had great value, showing through radio-opaque double-ring shadow, in unnoticed ingestion.⁵ Most of the cases with foreign body ingestion and aspiration are first presented to a pediatrician or a physician in an emergency unit.^{3,5} As the management is removal of foreign body under general anesthesia parents should be advised to keep the patient nil per oral. If the parents are giving the history of possibility of foreign body battery ingestion or the x-ray is showing double ring shadow foreign body or the foreign body is at mid-esophageal level parents should be informed about the seriousness of the situation. Same thing should be clearly mentioned in the referral card. At the same time parents should be instructed to not the feed the child anything by mouth so that removal of foreign body under general anesthesia can be done without any delay.

The key to proper management of button battery foreign bodies is rapid diagnosis and removal of any object lodged in the ear, nose, and upper aerodigestive tract that is suspicious for a button battery.^{3, 8, 11}

The increasing prevalence of lithium ion disc battery ingestion, as recorded by US registries, has led to the drafting of a proposed 'Button Cell Battery Safety Act of 2011' by the US Senate. Jatana et al.¹² suggested that until safer battery technology is developed and common in the market place, securing the

battery compartment of the product is the single most important intervention required to prevent battery ingestion injuries. Parent and caregiver education is needed to eliminate those left out, loose. Finally, battery package redesign with child-resistant packaging enclosing each battery in the package has the potential to further reduce ingestions.¹²

Serious battery ingestion complications are related to local corrosive injury rather than systemic poisoning from battery contents. Litovitz T et al.¹³ recommended that product manufacturers need to redesign battery-powered household products to secure the battery compartment, for example by requiring a readily available tool, such as a screwdriver, to open the compartment.⁹

The Button Battery Task Force has been formed for 'A collaborative effort of representatives from relevant organizations in industry, medicine, public health and government to develop, coordinate and implement strategies to reduce the incidence of button battery injuries in children.'¹²

V. CONCLUSION

This present study concludes that foreign body button cell battery cases are increasing but there is delay in reporting and referral of patient. General public should be informed for the hazards due to accidental ingestion of batteries and the prompt management required. Action is also required from the manufacturers of electronic devices to secure and fix these batteries properly.

CONFLICT OF INTEREST

None declared till now.

REFERENCES

- [1]. Nandi P, Ong GB. Foreign body in the oesophagus: review of 2394 cases. *Br J Surg* 1978; 65:5-9.
- [2]. Birchell MA, Croft CB, compilers. In: Brown's otolaryngology, Examination and Endoscopy of the upper aerodigestive tract. Great Britain: Butterworth-Heinemann; 1997. pp. 1-14.
- [3]. Centers for Disease Control and Prevention (CDC). Injuries from batteries among children aged <13 years--United States, 1995-2010. *MMWR Morb Mortal Wkly Rep*. 2012 Aug 31;61(34):661-6.
- [4]. Chiang MC, Chen YS. Tracheoesophageal fistula secondary to disc battery ingestion. *Am J Otolaryngol*. 2000;21:333-6.
- [5]. Dawe N, Puvanendran M, Flood L. Unwitnessed lithium ion disc battery ingestion: case report and review of best practice management of an increasing clinical concern. *J Laryngol Otol*. 2013 Jan;127(1):84-7.
- [6]. Harjai MM, Ramalingam W, Chitkara G, Katiyar A. Corrosive tracheo-esophageal fistula following button battery ingestion. *Indian Pediatr*. 2012 Feb;49(2):145-6.
- [7]. James S. Reilly. Coin-size lithium batteries can cause serious injury, death in a matter of hours if swallowed. *AAP News* 2013;34:13.
- [8]. Thabet MH, Basha WM, Askar S. Button battery foreign bodies in children: hazards, management, and recommendations. *Biomed Res Int*. 2013;2013:846091.
- [9]. Litovitz T, Whitaker N, Clark L. Preventing battery ingestions: an analysis of 8648 cases. 2010;125(6):1178-83.
- [10]. Chan YL, Chang SS, Kao KL, Liao HC, Liaw SJ, Chiu TF, et al. Button battery ingestion: an analysis of 25 cases. *Chang Gung Med J*. 2002;25:169-74.
- [11]. Akhtar M, Haq MI. Management of oesophageal foreign bodies. *Professional Med J* 2008; 12: 308-11.
- [12]. Jatana KR, Litovitz T, Reilly JS, Koltai PJ, Rider G, Jacobs IN. Pediatric button battery injuries: 2013 task force update. *Int J Pediatr Otorhinolaryngol*. 2013 Sep;77(9):1392-9.
- [13]. Toby Litovitz, Nicole Whitaker, Lynn Clark, Nicole C. Emerging Battery-Ingestion Hazard: Clinical Implications *Pediatrics* 2010;125:1168.