

# Retinal thickness in multiple sclerosis: evaluation with optical coherence tomography

Dr. Vesela Ivancheva<sup>1§</sup>, Dr. Diana Marinova<sup>2</sup>, Maya Danovska<sup>3</sup>

<sup>1</sup>Oculus Eye Center, Medical University of Pleven, <sup>3</sup>Department of Neurology, UMHAT, Pleven, Bulgaria (Europe)

<sup>2,3</sup>Department of Neurology, Medical University of Pleven, UMHAT, Pleven, Bulgaria (Europe)

<sup>§</sup>Corresponding author's Email: dr.ivancheva@gmail.com

**Abstract**— *In various neurodegenerative diseases ocular manifestations are very common which can be examined and monitored in vivo by a novel imaging technique Optical Coherence Tomography (OCT). So this study was conducted to compare retinal nerve fiber layer (RNFL) thickness and ganglion cell complex (GCC) between multiple sclerosis (MS) patients and healthy individual by optical coherence tomography (OCT). For this study 40 eyes of twenty consecutive MS patients and 40 eyes of 20 age matched healthy controls were taken. Comprehensive standardized ophthalmic examinations included visual acuity, cycloplegic refraction, color vision and intraocular pressure. Optical coherence tomography was performed using 3D Topcon OCT; RNFL thickness and ganglion cell complex (GCC) was detected with the inbuilt software. Mean values for the thickness of the peripapillary RNFL and ganglion cell complex (GCC) were calculated and compared between both groups. It was observed that the RNFL thickness in each quadrant and ganglion cell complex (GCC) in MS patients were all significantly decreased in comparison to healthy controls. So it can be concluded that OCT is a valuable research instrument for evaluation and monitoring MS progression by measurement of the retinal nerve fiber layer (RNFL) as purely axonal structure (indicative for axonal loss) and the macular ganglion cell complex (evidence of neuronal loss).*

**Keywords:** *Optical Coherence Tomography, Multiple Sclerosis, Retinal Nerve Fiber Layer Thickness.*

## I. INTRODUCTION

Pathology of central nervous system (CNS) has eye manifestations. They are due to retrograde and/or direct degeneration of the visual pathways, mostly related to a direct injury to the optic nerve, retinal ganglion cell layer and/or its surrounding cells.<sup>1</sup> Histopathologic studies have reported retinal nerve fiber layer (RNFL) thinning in various neurodegenerative diseases.<sup>2</sup>

These ocular manifestations can be examined and monitored in vivo by a novel imaging technique Optical Coherence Tomography (OCT). OCT has revolutionized ophthalmology and it has recently become a vital tool for clinicians and researchers in neuro-ophthalmic practice. It is non-invasive, high resolution technique that provides in vivo cross-sectional images of tissues that resemble histological analysis. The image resolution (up to 5µm) allows us to search about axonal-neuronal integrity in the afferent visual pathway and is faster, more reproducible, precise and less dependent on patient compared to perimetry. It can detect CNS inflammatory and degenerative pathology, such as Multiple Sclerosis, at possibly subclinical stages. It has a potential of quantifying neuroaxonal loss in MS, and the increasing acceptance of the anterior visual pathway as a model to investigate this disease.

It was hypothesized that OCT imaging of the retina in patients with multiple sclerosis may provide a high-resolution, objective, noninvasive, and easily quantifiable in vivo biomarker of severity of disease and presence of optic neuritis. The purpose of this study was to compare retinal nerve fiber layer

(RNFL) thickness and ganglion cell complex (GCC) between multiple sclerosis (MS) patients and aged matched healthy individuals using 3D Topcon 2000 FA+ OCT.

## II. METHODOLOGY

This was a hospital based case control type of observational study conducted on forty eyes of twenty consecutive MS patients (with more than 5 years of diagnose, mean age  $39\pm 7$  years, 10 male and 10 female) and 40 eyes of 20 age matches healthy controls (mean age  $40\pm 5$  years, 11 male and 9 female). All of them underwent a complete ophthalmic examination including best corrected visual acuity examination, slit-lamp examination, Goldman applanation tonometry, and dilated stereoscopic fundus examination. Subjects having optic neuritis (ON) in the past or now, refractive error  $> \pm 5.0$  diopters sphere and/or  $\pm 3.0$  diopters cylinder, IOP  $> 21$ mmHg, eyes with retinopathy of any cause, eyes with glaucomatous disc changes were excluded from study.

**Ethical approval:** “All procedures performed in studies involving human participants were in accordance with the ethical standards of the institutional and/or national research committee and with the 1964 Helsinki declaration and its later amendments or comparable ethical standards. Informed consent was obtained from all individual participants included in the study.

All subjects were examined using standard protocols: 3D Disc  $6\text{mm}\times 6\text{mm}$ , 3D Macula  $6\text{mm}\times 6\text{mm}$  and 3D Macula (V)  $7\text{mm}\times 7\text{mm}$  with 3D Topcon 2000 FA + (Topcon, Tokyo, Japan).

The 3D Macula scanning protocol was with  $6\text{mm}\times 6\text{mm}$  volume cube scans and  $512\times 128$  pixels scan resolution, scan depth 2.3mm, horizontal resolution  $20\ \mu\text{m}$ , longitudinal resolution 5-6  $\mu\text{m}$ . Macular thickness was reported in a modified Early Treatment of diabetic retinopathy study, macular map with a center subfield of 1 mm in diameter and the inner and outer subfields having diameters of 3 mm and 6 mm respectively. The mean Central Foveal Thickness (CFT), the mean Center Point Thickness (CPT) and the mean macular volume were calculated. At OCT scans center macular thickness was determined automatically and was analyzed by OCT software. In all OCT maps, automated macular thickness detection was performed by instrument’s software analysis without macular operator adjustment.

The RNFL thickness was measured using 3D Disc scanning protocol with  $6\text{mm}\times 6\text{mm}$  volume cube scans,  $512\times 128$  pixels scan resolution, scan depth 2.3 mm, horizontal resolution  $20\ \mu\text{m}$ , longitudinal resolution 5-6  $\mu\text{m}$ . The RNFL thickness was measured around the disc with 16 averaged consecutive circular B-scans with diameter of 3.4 mm and 1024 A-scans. The peripapillary RNFL thickness (average and four quadrant values) was analyzed.

3D Macula (V) scanning protocol with  $7\text{mm}\times 7\text{mm}$  volume cube scans and  $512\times 128$  pixels scan resolution allows three types of thickness measuring : Nerve Fiber Layer (NFL), Ganglion Cell Layer (GCL)+ Inner Plexiform Layer (IPL), NFL+ GCL+ IPL. The average thickness of these layers was calculated.

Age stratified comparisons of all macular and RNFL measurements between groups were carried out using the independent sample t-test or ANOVA. For significance  $p < 0.05$  was considered to be statistically significant. All analyses were performed using SPSS software, version 19.0.

## III. RESULTS

Peripapillary and macular OCT imaging was performed on 40 eyes of patients with multiple sclerosis. No images were excluded from the final analysis due to poor image quality. Patient age ranged from 26

to 69 years (median 39.7 years). The percentage of subjects who were female was 50%. Disease duration for all subjects with multiple sclerosis was at least 5 years.

The Macular Total Volume in MS patients was decreased compared to healthy controls, with statistically significant differences. Mean Macular Total Volume for MS patients was  $7.84 \pm 0.13 \text{ mm}^3$ . For healthy controls mean Macular Total Volume was  $8.34 \pm 0.22 \text{ mm}^3$ .

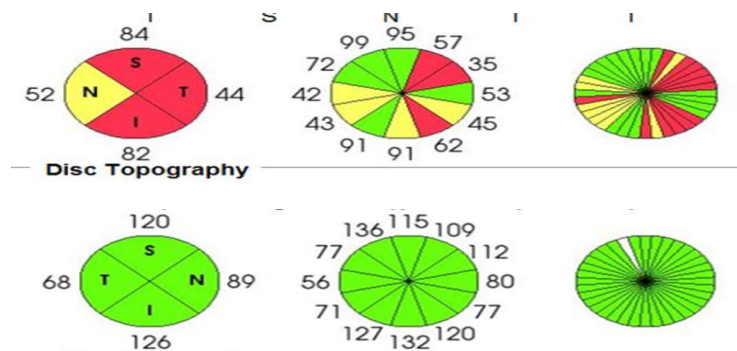
Peripapillary RNFL thinning was demonstrated: mean thickness was  $105.2 \pm 3.8 \text{ }\mu\text{m}$  ( $P < 0.001$ ) for individuals with multiple sclerosis when compared with eyes of patients without multiple sclerosis (normals,  $114.3 \pm 2.93 \text{ }\mu\text{m}$ ).

The ganglion cell complex (GCC) in MS patients were all decreased compared to healthy controls, with statistically significant differences. Mean thickness for MS patients was  $46 \pm 12.0 \text{ }\mu\text{m}$  for GCL+ and  $59 \pm 13.1 \text{ }\mu\text{m}$  for GCL++. For healthy controls mean thickness was  $76 \pm 0.20 \text{ }\mu\text{m}$  for GCL+ and  $118 \pm 0.12 \text{ }\mu\text{m}$  for GCL++.

Lower values of peripapillary RNFL thickness (Figure 1), GCL-IPL thickness (Figure 2), Macular Total Volume, Average Thickness and Center Thickness (Figure 3) found in the group of MS patients in comparison with the healthy controls. (Table 1)

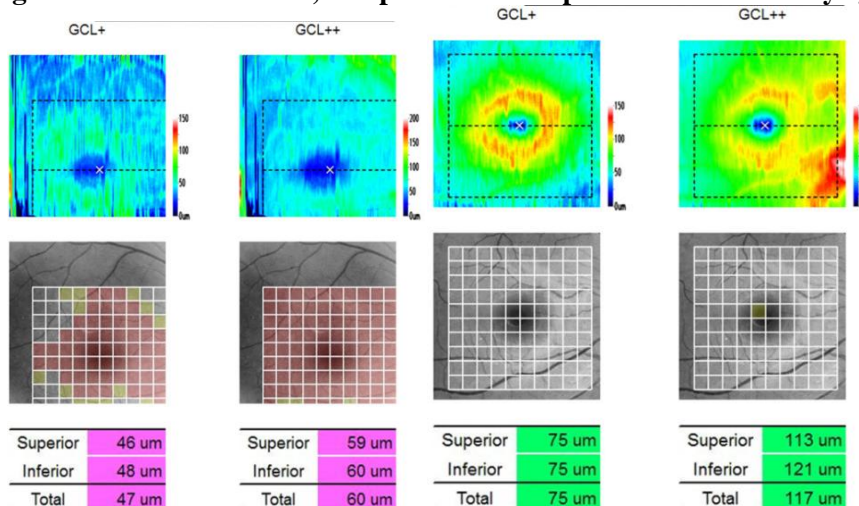
**Figure 1**

**OCT image in a patient with multiple sclerosis (upper image) and healthy control eye (bottom image). Upper image shows overall thinning of pRNFL (depicted by yellow and red codes).**



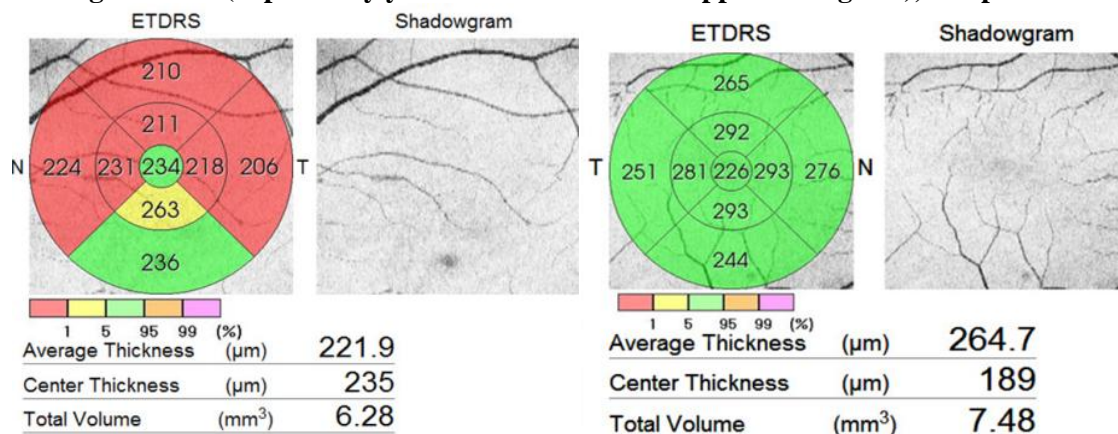
**Figure 2**

**OCT image in a patient with multiple sclerosis (left image) and healthy eye (right image). Left image shows overall thinning of GCL+ and GCL++ , compared to same parameters in healthy eye (right image)**



**Figure 3**

OCT image in a patient with multiple sclerosis (left image) and healthy eye (right image). Left image shows overall thinning of retina (depicted by yellow and red codes in upper nomogram), compared to healthy eye.



**Table 1**

**Comparison of OCT in healthy controls (HCs) and patients with multiple sclerosis (MS)**

S. No.	Variables	Study Group (N=40) Mean ±SD	Control Group (N=40) Mean ±SD	'P' Value
1	Macula: Total Volume	7.84±0.13 mm <sup>3</sup>	8.34±0.22 mm <sup>3</sup>	p<0.001
2	Macula: GCL+	46±12.0 μm	76±0.20 μm	p<0.001
3	Macula: GCL++	59±13.1 μm	118±0.12 μm	p<0.001
4	pRNFL	105.2±3.8 μm	114.3±2.93 μm	p<0.001

#### IV. DISCUSSION

In this present study, a reduced RNFL thickness in MS patients compared to healthy controls is demonstrated herein, in agreement with other recently reported results.

Thinning of pRNFL by OCT in MS patients is firstly reported in 1999 by Parisi. He described it as structural marker of axonal degeneration in MS, which occurs even without optic neuritis (ON) antecedent.<sup>3</sup> RNFL thickness correlates with MS duration as well as with visual and neurological functioning. The strongest correlations were shown in studies including MS patients with a history of ON.<sup>4,5</sup> Meta-analyses of data for TD-OCT show that RNFL thinning is more pronounced in the temporal quadrant and is milder in MS without previous ON compared to eyes with a history of ON.<sup>5</sup>

A moderate association has also been shown between the RNFL thickness and brain atrophy in MS patients. Scheel et al. used several magnetic resonance imaging (MRI) findings characteristic of brain atrophy and proved that RNFL changes indicate white matter damage exceeding the visual pathway.<sup>6</sup> However, a strong correlation with MRI results is unlikely because brain atrophy reflects not only loss of axons, but also loss of other components of brain tissue: myelin, gliosis, synaptic and water content.

A recent study of Balk et al. investigated the timing of central nervous system tissue atrophy in MS by evaluating longitudinal retinal volume changes demonstrated a significant decrease over 2 years of the pRNFL (-1.1 μm, 95 % CI 1.4-0.7, p < 0.001). Thinning was most pronounced early in the course of disease, irrespective of previous ON.<sup>7</sup>

Initially, pRNFL and its evaluation was the prime focus of OCT examinations. Lately, OCT investigations focus on retinal layers segmentation analysis, which allows quantification of both axonal damage and neuronal degeneration. A few studies show that patients with RRMS exhibit a significant

thinning of ganglion cell layer (GCL), not only pRNFL. The damage was more pronounced in eyes with a history of ON. A study of Garcia-Martin in 2014 proves that GCL thickness analysis is more sensitive to detect damage. GCL is reduced before pRNFL in RRMS patients, even in eyes without previous ON.<sup>8</sup> Macular GCL thickness correlates better with visual dysfunction, disability and MRI in comparison to RNFL thickness.<sup>9,10</sup> Patients with MS have progressive RNFL and ganglion cell inner plexiform layer (GCIPL) thinning, that is a function of time and is associated with clinically significant visual loss. Narayanan reported that RNFL and GCIPL decreased with follow-up time.<sup>11</sup> Progressive changes seem to correlate with changes in neurological impairment measured by the Expanded Disability Status Scale (EDSS).

OCT may not only evaluate axonal and neuronal loss after each episode of ON, but also could monitor these changes and predict visual recovery. Costello et al. found a threshold of RNFL thickness (75  $\mu\text{m}$ ) below which RNFL measurements predicted persistent visual dysfunction with TD-OCT.<sup>12</sup> Recently, same authors use SD-OCT to confirm these findings. Both one-month RNFL and GCIPL values after ON predicted change in visual field MD and VA at 6 and 12 months [13]. In eyes with acute anterior optic neuritis and swelling, RNFL measurements can underestimate the amount of true damage and could mask the true degree of RNFL loss. On the other hand, macular thickness and GCL measurements are not influenced by the optic disc edema and could be more useful for detecting the structural changes in the first month compared to RNFL evaluation.<sup>13</sup> Therefore GCL thinning might be considered a biomarker of early structural loss.

Research on individual layers of the retina opens new perspectives in MS. Saidha et al. identify a subgroup of MS patients with a unique model of retinal neuronal loss of cells (predominantly macular thinning phenotype) who seems to have a disproportionate thinning of the inner and outer nuclear layers with relative sparing of GCL and more rapid progression of disability.<sup>14</sup> These findings support the possibility that preclinical retinal pathology could be harbinger of a more aggressive form of MS.

In Bulgaria, only a few studies of OCT in MS patients were performed. In 2013, Vladimirova and Cherninkova examined 20 MS patients with ON. They found thinning of the RNFL layer in most patients, with the changes observed being less marked than these in patients with ON in the past.<sup>15</sup> In another study Z. Vladimirova examined a total 101 MS patients (eyes with acute ON, ON in the past and with no history for ON). The results demonstrated substantial thinning of the RNFL and GCC in the eyes with ON in the past, more severe in comparison to patients with acute ON. The patients who have never had ON were also found to have changes in the thickness of these layers, although less advanced, which demonstrates the presence of asymptomatic loss of vision in MS patients.<sup>16</sup> Both studies used FD-OCT RTVue-100 unit; Optovue, to perform the OCT examination.

## V. CONCLUSION

Patients with a history of multiple sclerosis had RNFL thinning that was detectable on OCT. OCT is a valuable research instrument for evaluation and monitoring MS progression by measurement of the retinal nerve fiber layer as purely axonal structure (indicative for axonal loss) and the macular ganglion cell complex (evidence of neuronal loss). Future prospective investigations of multiple sclerosis-related retinal changes should consider these findings when following subjects longitudinally. More precise high resolution OCT scans may be able to diagnose systemic diseases much earlier, with high sensitivity and specificity through ocular manifestations.

Nowadays OCT is essential for assessing the effectiveness of non-invasive therapies that reduce axonal and neuronal loss by neuroprotective or myelin repair mechanisms. For research and therapeutic purposes focused at loss of axons, degeneration of neurons, or both, a combination of RNFL plus individual macular layers can give the most complete picture of disease activity in MS and ON. Developments, which could improve the understanding of MS in the future include OCT angiography, polarization-sensitive OCT (PS-OCT) and fluorescence labeling.

The retinal changes reported here need to be validated in multiple sclerosis disease subsets, and correlated with magnetic resonance imaging findings and measures of visual function. Nonetheless, as our findings demonstrate, OCT retinal imaging may represent a high-resolution, objective, noninvasive, and easily quantifiable in vivo biomarker of the severity of multiple sclerosis. It may also serve as a diagnostic adjunct for monitoring disease activity and response to treatment.

### CONFLICT OF INTEREST

None declared till now.

### REFERENCES

- [1]. Huang D, Swanson E, Lin CP, et al. Optical Coherence Tomography. *Science*, 1991; 254: 1178-1181.
- [2]. Chen TC, Cense B, Miller JW, et al. Histologic correlation of in vivo Optical Coherence Tomography- images of the human retina. *Am J Ophthalmol*, 2006; 141: 1165-1168.
- [3]. Parisi V, Manni G, Spadaro M, Colacino G, Restuccia R, Marchi S, et al. Correlation between morphological and functional retinal impairment in multiple sclerosis patients. *Invest Ophthalmol Vis Sci* 1999;40:2520-7.
- [4]. Noval S, Contreras I, Munoz S, Oreja-Guevara C, Manzano B, Rebolleda G. Optical coherence tomography in multiple sclerosis and neuromyelitisoptica: an update. *MultSclerInt* 2011;2011: 472790
- [5]. Petzold A, de Boer JF, Schippling S, Vermersch P, Kardon R, Freen A, et al. Optical coherence tomography in multiple sclerosis: a systematic review and meta-analysis. *Lancet Neurol* 2010;9:921-32.
- [6]. Scheel M, Finke C, Oberwahrenbrock T, Freing A, Pech LM, Schlichting J, et al. Retinal nerve fibre layer thickness correlates with brain white matter damage in multiple sclerosis: A combined optical coherence tomography and diffusion tensor imaging study. *MultScler* 2014 Dec;20(14):1904-7
- [7]. Balk LJ1, Cruz-Herranz A2, Albrecht P3, et al Timing of retinal neuronal and axonal loss in MS: a longitudinal OCT study. *J Neurol*. 2016 May 3. [Epub ahead of print]
- [8]. Garcia-Martin E, Polo V, Larrosa JM, Marques ML, Herrero R, Martin J, et al. Retinal layer segmentation in patients with multiple sclerosis using spectral domain optical coherence tomography. *Ophthalmology* 2014;121: 573-9.
- [9]. Gonzalez JJ, Rebolleda G, Leal M, Oblanca N, Muñoz-Negrete FJ, Costa-Frossard L, Alvarez-Cermeño JC. Comparative diagnostic accuracy of ganglion cell-inner plexiform and retinal nerve fiber layer thickness measures by Cirrus and Spectralis OCTs in relapsingremitting multiple sclerosis. *Biomed Res Int* 2014; Volume 2014, Article ID 128517, 10
- [10]. Saidha S, Syc SB, Durbin MK, Eckstein C, Oakley JD, Meyer SA, et al. Visual dysfunction in multiple sclerosis correlates better with optical coherence tomography derived estimates of macular ganglion cell layer thickness than peripapillary retinal nerve fiber layer thickness. *MultScler* 2011;17:1449-63.
- [11]. Narayanan D, Cheng H, BokemKN,Tracking changes over time in retinal nerve fiber layer and ganglion cell-inner plexiform layer thickness in multiple sclerosis. *MultScler* 2014 Sep;20(10):1331-41.
- [12]. Costello F, Hodge W, Pan YI, Eggenberger E, Coupland S, Kardon RH. Tracking retinal nerve fiber layer loss after optic neuritis: a prospective study using optical coherence tomography. *MultScler* 2008;14:893-905.
- [13]. Costello F, Pan YI, Burton J, Chan W, Hodge W. Predicting visual recovery after optic neuritis. In: 40th NANOS (North American Neuro-Ophthalmology Society) meeting, Rio Grande, Puerto Rico, USA: Annual Meeting Syllabus; 2014. p. 319.
- [14]. Saidha S, Syc SB, Ibrahim MA, Eckstein C, Warner CV, Farrell SK, et al. Primary retinal pathology in multiple sclerosis as detected by optical coherence tomography. *Brain* 2011; 134: 518-33.
- [15]. Vladimirova Z., S. Cherninkova OPTICAL COHERENCE TOMOGRAPHY (OCT) N PATIENTS wITH MULTIPLE SCLEROSIS wITH ACUTE OPTIC NEURITIS, *Bulgarian neurology*, Feb 2013: 25-30
- [16]. Vladimirova Z. Optical coherence tomography in multiple sclerosis, PhD Thesis, Department of Neurology, Medical University of Sofia, 2014.