

Mefenamic acid induced Acute Generalized Exanthematous Pustulosis (AGEP): A Case Report

Dr. Elangbam Nelson Singh¹, Dr. Chaitra Prakash², Dr. Uma Shankar Agarwal³,
Dr. Manoj Verma^{4§}

¹Junior Resident, Department of Skin and VD, SMS Medical College, Jaipur (Rajasthan) India

²Senior Resident, Department of Skin and VD, SMS Medical College, Jaipur (Rajasthan) India.

³Senior Professor, Department of Skin and VD, SMS Medical College, Jaipur (Rajasthan) India

⁴Senior Resident, Department of Community Medicine, All India Institute of Medical Science, Jodhpur (Rajasthan) India

Abstract— *Acute Generalized Exanthematous Pustulosis (AGEP) is a rare severe cutaneous adverse reaction mainly caused by drugs. It is characterized by an acute pustular eruption over the body along with fever and leukocytosis. It has been known to resolve spontaneously over a period of 2-3 weeks without long term sequelae. However it is of utmost importance for the physicians to clinically identify this condition as to prevent unwanted extensive management. Mefenamic acid is a non-steroidal anti-inflammatory drug (NSAIDs) prescribed over the counter for pain relief. A sixteen year old boy is reported here who developed AGEP after taking mefenamic acid for fever and joint pain. It was diagnosed with the help of history, clinicopathological correlation, AGEP validation score and recovery on withdrawal of the drug. To the best of our knowledge this is the first case report of mefenamic acid causing AGEP in the literature.*

Keywords: *Mefenamic acid, Acute Generalized Exanthematous Pustulosis, AGEP*

I. INTRODUCTION

Acute Generalized Exanthematous Pustulosis (AGEP) is an immune-mediated severe cutaneous adverse reaction characterized by an acute eruption of sterile non-follicular pinpoint pustules over an erythematous background having predilection of flexural sites such as neck, axilla and inguinal areas. It was first described by Baker and Ryan in 1968 amongst the patients of pustular psoriasis.¹ The term AGEP was given by Beylot in 1980.² The incidence of AGEP is estimated to be 1-5 per million per year.³ In more than 90% cases, drugs are the etiological agents and others are viral infections, insect bites, herbal medicines, mercury ingestion etc.⁴

The most commonly implicated drugs include antibiotics (aminopenicillins, macrolides, sulphonamides, fluoroquinolones), anti-malarials like chloroquine and hydroxychloroquine, anti-fungals like terbinafine, diltiazem etc. Roujeau et al⁵ and Sidoroff et al⁶ in their studies distinguished AGEP from pustular psoriasis and focused mainly on the drugs as etiological agents. A sixteen year old boy is reported here who developed AGEP after taking mefenamic acid for fever and joint pain.

II. METHODOLOGY

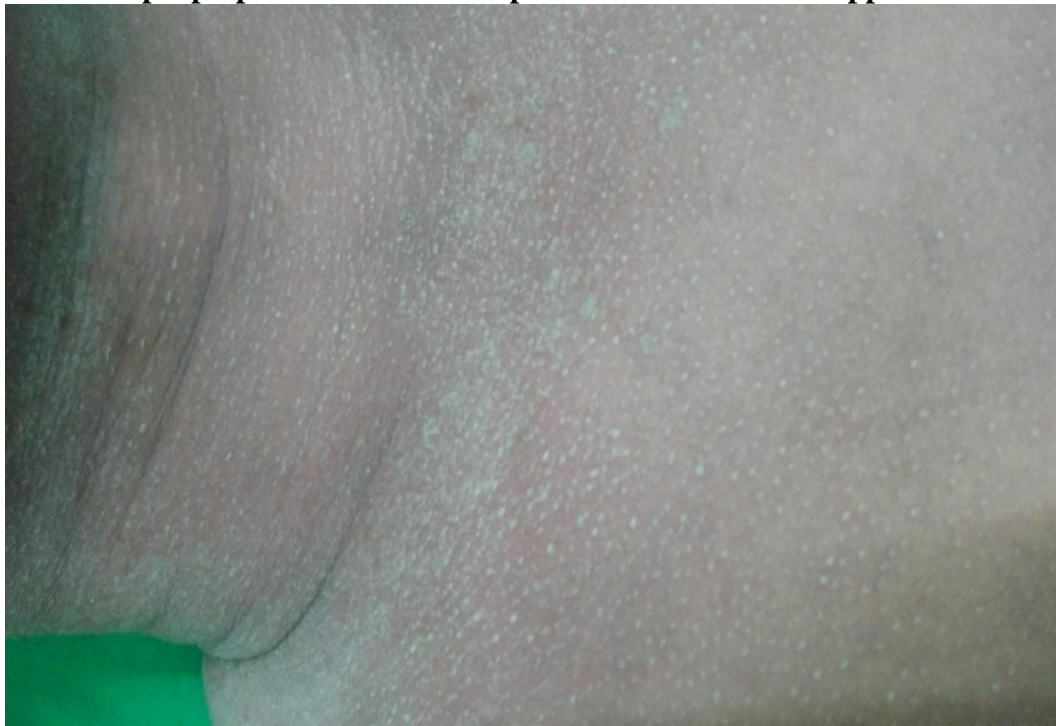A boy presented with fever, sore throat, headache, arthralgia along with diffuse erythema and non-follicular minute pustules over neck and upper trunk for the past 4 days at the Skin OPD at SMS hospital, Jaipur (Rajasthan) India. After examination and investigations this case was came out of a rare case of Acute Generalized Exanthematous Pustulosis (AGEP). So case was studied in detailed and case report was prepared.

III. RESULTS

A sixteen year old male boy presented to the Skin OPD at SMS hospital, Jaipur with fever, sore throat, headache, arthralgia along with diffuse erythema and non-follicular minute pustules over neck and upper trunk for the past 4 days. He had a history of intake of mefenamic acid 100 mg one tablet 4 days back for fever and headache. Then next day, he had redness, burning sensation and itching followed by development of numerous minute pinpoint pustules of size less than 5 mm over neck and upper trunk within few hours. There was no past, personal or family history suggestive of psoriasis.

On examination, he was febrile with a temperature of 38.4 degree Celsius along with facial edema and bilateral non-tender inguinal lymphadenopathy. Other systemic examination was unremarkable except for decreased mobility of joints due to arthralgia. On dermatological examination, numerous non-follicular, discrete as well as coalescing pustules of almost pinhead size were present over neck and upper trunk (Figure 1). Examination of mucosa, hair, nails, palms and soles did not reveal any abnormality. Nikolsky's sign was negative.

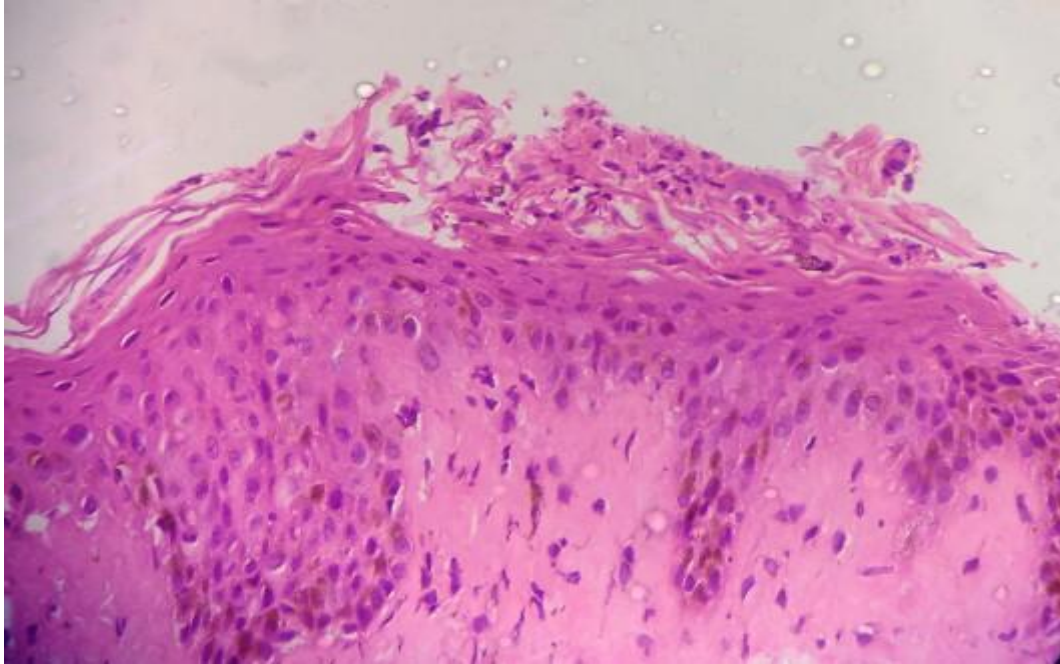
Figure 1
Multiple pinpoint non-follicular pustules over neck and upper trunk



His blood tests showed neutrophilia, eosinophilia and lymphocytopenia, raised erythrocyte sedimentation rate (50 mm at 1st hour), serum calcium (8.4 mg/dl), aspartate transaminase (44 IU/L) and elevated C-reactive protein. Other blood parameters were within normal limits. He was subjected to investigations to rule out common infective causes of fever (malaria, typhoid, dengue, chikungunya). He tested positive for chikungunya by IgM antibody serology. Ultrasound abdomen was insignificant. Pus culture and sensitivity from pustules was sterile. Histopathology of the skin biopsy specimen revealed spongiosis, intraepidermal and subcorneal neutrophilic infiltrate along with perivascular mixed inflammatory infiltrate in the dermis consistent with the diagnosis of AGEP (figure 2).

Figure 2

Epidermis showed spongiosis, intraepidermal and subcorneal neutrophilic infiltrate along with perivascular mixed inflammatory infiltrate in the dermis (H & E stain, 40 x magnifications)



The AGEP score of the patient was calculated to be 10 where 1-4 score denotes possible AGEP, 5-7 score denotes probable AGEP and 8-12 score denotes definite AGEP according to EuroSCAR study group.⁶

Patient was withheld from mefenamic acid. For severe arthralgia he was prescribed tramadol as required. For skin lesions he was prescribed topical steroids and emollients. After 7 days he got relief from fever and his skin lesions started to resolve. In 3 weeks all his skin lesions cleared spontaneously. On the basis of history, clinical features, histopathology and AGEP validation score of 10 (EuroSCAR study group) in this patient, a final diagnosis of AGEP due to mefenamic acid was made.

IV. DISCUSSION

AGEP is one of the severe cutaneous adverse reaction (SCAR) syndromes which are mainly caused by drugs. It also includes drug reaction with eosinophilia and systemic symptoms (DRESS), drug-induced generalized exfoliative dermatitis and Stevens-Johnson syndrome/toxic epidermal necrolysis (SJS-TEN). AGEP presents with an acute episode of pustular skin eruption along with fever and mild systemic derangement which resolves spontaneously without complications. It is believed to be a T-cell mediated phenomenon wherein the drug metabolites elicit a drug-specific CD4+ and CD8+ T-cell activation and release of neutrophil-attracting factors such as chemokines IL-8, CXCL-8⁷. This leads to accumulation of neutrophils in already oedematous skin creating pustules.

The management generally aims at withdrawal of offending drugs and application of topical steroids in mild cases and oral steroids in case of extensive involvement with systemic derangement. It is generally associated with better prognosis as compared to other SCAR syndromes and full recovery is expected.

Mefenamic acid is an anthranilic acid derivative belonging to the group of non-steroidal anti-inflammatory drugs (NSAIDs) that inhibits prostaglandin synthesis. It is mainly used for relief of pain in dysmenorrhoea, menorrhagia and musculoskeletal pain. It has been known to induce fixed drug

eruptions (FDE), Bullous pemphigoid, Stevens - Johnson syndrome and linear IgA dermatosis as dermatological side effects.⁸

On the other hand, there have been reports of mucocutaneous manifestations associated with chikungunya fever. Viral exanthem as generalized maculopapular eruption, oral aphthae and aphthae like ulcers in the intertriginous areas, pigmentary changes mainly over the face are the most common manifestations.⁹ Vesico-bullous lesions may be seen in chikungunya but never pustules. In present case the presentation did not fit into the mucocutaneous manifestation of chikungunya fever. There have been previous case reports of NSAIDs causing AGEP mainly by Acetylsalicylic acid⁴, Piroxicam¹⁰ and Ibuprofen causing acute localized exanthematous pustulosis (ALEP).¹¹ However to the best of our knowledge, this is the first case of mefenamic acid causing AGEP and hence reported.

V. CONCLUSION

AGEP should be included in the differential diagnosis of patient presenting with pustular skin lesion and history of NSAID intake including mefenamic acid. Clear drug history should be taken as unreported drugs may also cause AGEP.

CONFLICT OF INTEREST

None declared till now.

REFERENCES

- [1] Baker H, Ryan TJ. Generalized pustular psoriasis. A clinical and epidemiological study of 104 cases. *Br J Dermatol* 1968; 80:771- 9.
- [2] Beylot C, Bioulac P, Doutre MS. Acute generalized exanthematous pustuloses (four cases). *Ann Dermatol Venereol* 1980; 107: 37-48.
- [3] Sidoroff A, Halevy S, Bavinck JN, Vaillant L, Roujeau JC. Acute generalized exanthematous pustulosis (AGEP) – a clinical reaction pattern. *J Cutan Pathol* 2001; 28:113-19.
- [4] Bahuguna A. Acute generalized exanthematous pustulosis: A rare side effect of a common over-the-counter drug, Acetylsalicylic acid. *Indian Dermatol Online J* 2013; 4:231-3.
- [5] Roujeau JC, Bioulac-Sage P, Bourseau C, Guillaume JC, Bernard P, Lok C et al. Acute generalized exanthematous pustulosis. Analysis of 63 cases. *Arch Dermatol* 1991; 127:1333-1338.
- [6] Sidoroff A, Dunant A, Viboud C, Halevy S, Bavinck JN, Naldi L et al. Risk factors for acute generalized exanthematous pustulosis (AGEP): results of a multinational case-control study (EuroSCAR). *Br J Dermatol* 2007; 157:989-996.
- [7] Britschgi M, Steiner UC, Schmid S, Depta JP, Senti G, Bircher A et al. T-cell involvement in drug-induced acute generalized exanthematous pustulosis. *J Clin Invest* 2001; 107:1433-41.
- [8] Pérez-Pérez L et al. Exantema fijo medicamentoso múltiple probablemente inducido por ácido mefenámico. *Actas Dermosifiliogr*.2013; 104:85-7.
- [9] Bhat RM, Rai Y, Ramesh A, Nandakishore B, Sukumar D, Martis J, Kamath GH. Mucocutaneous manifestations of chikungunya fever: A study from an epidemic in coastal Karnataka. *Indian J Dermatol* 2011; 56:290-4.
- [10] Cherif Y, Jallouli M, Mseddi M, Turki H, Bahloul Z. Acute generalized exanthematous pustulosis induced by piroxicam: A case report. *Indian J Pharmacol* 2014; 46:232-3.
- [11] Rastogi S, Modi M, Dhawan V. Acute localized exanthematous pustulosis (ALEP) caused by Ibuprofen. A case report. *Br J Oral Maxillofac Surg* 2009; 47:132-4.