

Chikungunya fever in children: A Descriptive Study

Dr. Priyanka Udawat¹, Dr. Kusum Devpura², Dr. Pukhraj Kheretia³, Dr. Deepesh Gupta⁴,
Dr. Ghanshyam Swami⁵

¹Assistant Professor, Department of Pediatric Medicine, SMS Medical College, Jaipur (Rajasthan) India.

²Professor, Department of Pediatric Medicine, SMS Medical College, Jaipur (Rajasthan) India

³P G Student, Department of Pediatric Medicine, SMS Medical College, Jaipur (Rajasthan) India

⁴P G Student, Department of Pediatric Medicine, SMS Medical College, Jaipur (Rajasthan) India

⁵Assistant Professor, Department of Pediatric Medicine, SMS Medical College, Jaipur (Rajasthan) India

Abstract—*In the Indian sub-continent, first isolation of the chikungunya virus was done in Kolkata during 1963. During 2006 reports of large scale outbreaks in several parts of India have confirmed the re-emergence of this virus in the country. Since the incidence of this disease is increasing. So a retrospective analysis of laboratory confirmed chikungunya patients admitted to pediatric ward was done to study biochemical profile of chikungunya fever in children. Total 51 children were laboratory confirmed for chikungunya, 36 of them had isolated chikungunya infection. Male/female ratio of isolated chikungunya was 2.6:1. Fever was invariably present, associated constitutional symptoms consisted of skin rash, vomiting, diarrhea, pain abdomen, cough, coryza, myalgia and bleeding manifestations. The most characteristic feature of the infections in infants was skin manifestations in form of symmetrical superficial vesiculobullous lesions & maculopapular erythematous rash. Nine patients (25%) had neurological manifestations. Joint pain was present in only three patients but none had arthritis. Most common hematological abnormality revealed thrombocytopenia in 39% cases. There was mild to moderate elevation of liver enzymes in 13 patients (36%). Average length of hospital stay was 5.1 days. Thirty four patients recovered completely & two left against medical advise. It is concluded from this study that skin manifestations and neurological manifestations are common in younger age group apart from other constitutional symptoms. Arthralgia and chronic polyarthritis is rare in this age group as found in adults.*

Keyword: *Chikungunya in Children; Viral Fever; Vesiculobullous Lesions.*

I. INTRODUCTION

Chikungunya was first isolated by R.W. Ross in 1952 in the Newala district of Tanzania.¹ It causes a dengue-like illness, characterized by fever, rash, painful myalgia and arthralgia and sometimes arthritis. In the Indian sub-continent, first isolation of the virus was done in Kolkata in 1963.^{2,3} In 2016, a big upsurge/epidemic of chikungunya affecting the capital city of Delhi and other states was observed.³

The chikungunya virus is an envelope, positive stranded RNA alphavirus belonging to the Togaviridae family and transmitted by Aedes mosquito bites (mainly *Ae. aegypti* and *Ae. albopictus*).⁴ The mosquito, well adapted to life in urban settings, breeds in clean puddles of stagnant water and collections of water in artificial containers. The mosquito is highly susceptible to the virus, prefers to live close to people, seeks a blood meal during day time and bites several people in a short period for one meal.⁵

Most descriptions of chikungunya fever are based on data obtained during epidemics mostly in adults. Children are among the group at maximum risk for severe manifestations of the disease and some

clinical features in this group are distinct from those seen in adults.^{5, 6} During the recent epidemic of chikungunya peculiar clinical pattern was observed.⁷ Children presenting with fever, skin manifestations, cough, corrhya, headache and diarrhea without joint manifestations were found to be positive for chikungunya IgM antibodies. Due to paucity of literature about detailed clinical profile and these atypical manifestations of the chikungunya fever in children, the study was carried out to analyze various manifestations of chikungunya cases in a tertiary care hospital in Rajasthan state in 2016.

II. METHODOLOGY

A retrospective analysis of laboratory confirmed chikungunya patients was done, who were admitted in pediatric wards of Sir Padampath Mother and Child Health Institute, SMS Medical College, Jaipur, Rajasthan, India from September 2016 to November 2016. The Government of Rajasthan is providing free health care to all. These cases were laboratory confirmed for chikungunya infection by detection of IgM antibodies against chikungunya virus (CHIKV IgM) and chikungunya virus nucleic acid in sera by reverse transcriptase–polymerase chain reaction (RT-PCR).

National guidelines for clinical management of Chikungunya³ issued in 2016 by Directorate of National Vector Borne Disease Control Programme, Ministry of Health and Family Welfare, Government of India defines:-

Confirmed (definitive) case: a patient meeting both the clinical and laboratory criteria

- **Clinical criteria:** Acute onset of fever and severe arthralgia / arthritis with or without skin rash and residing or having left an epidemic area 15 days prior to onset of symptoms.
- **Laboratory criteria:** At least one of the following tests done in the acute phase of illness
 - Direct evidence: Virus isolation / Presence of viral RNA by RT-PCR
 - Indirect evidence:
 - Presence of virus specific IgM antibodies in single serum sample collected in acute or convalescent stage.
 - Four-fold increase in IgG values in samples collected at least three weeks apart.

It was observed that Chikungunya IgM antibodies were found in patients without joint manifestations, so the target group consisted of patients presenting with fever with constitutional symptoms, with or without rashes, and arthralgia.

Besides routine investigations they were investigated for different etiopathologies to rule out common differentials such as dengue fever, malaria, enteric fever, reactive arthritis and scrub typhus. Chikungunya and Dengue IgM ELISA Test kits provided by National Institute of Virology (NIV), Pune and scrub typhus DetectTM ELISA kit by InBios International were used.

A total of 51 chikungunya cases were reported during the study period out of those 15 patients had co-infections consisting dengue fever, scrub typhus, enteric fever, and hepatitis-A. So, 36 isolated chikungunya infection cases were analyzed.

The bed head tickets, clinical records of those patients reviewed for clinical presentations at the time of admission, progression and outcome of illness. Routine investigations (total leucocytes count, differential leucocytes count, platelets count, and haemo-parasites in peripheral smear, liver function test, renal function test), specific biochemical and radiological investigations i.e. chest X-ray, USG abdomen were reviewed. Other significant investigations were also done according to the clinical manifestations.

The data thus collected from clinical records of hospital records these cases were compiled on Microsoft excel 2010 spread sheet and results were expressed in percentage.

III. RESULTS

A total number of 51 laboratory confirmed chikungunya patients were observed in this study period. Out of which, 15 (29.41%) patients had co-infections consisting dengue fever (6 cases), scrub typhus (3 cases), enteric fever (1 case), bacterial sepsis (*E. coli* in 2 cases and *Enterobacter* spp. 1 case), pyomeningitis (1 case) and hepatitis-A (1 case). So, finally 36 isolated chikungunya infection cases were analyzed for this study. Clinical presentation, progression of disease, hematological and biochemical profile and outcome of these cases were assessed and recorded.

Mean age of identified chikungunya patients was found 4.4 ± 4.7 years (range 25 days to 18 years) with male predominance (M:F ratio 2.6:1). Out of 36 patients, 16 (44.44%) were less than one year, 8 (22.22%) were more than one to 5 yrs and 12 (33.33%) were more than 5 years.

Table 1
Bio-demographic distribution of Chikungunya Cases (N=36)

Bio-demographic Variable	Number	Percentage (%)
Age		
<1 year	16	44.44
1-5 years	8	22.22
> 5 years	12	33.33
Sex		
Male	26	72.22
Females	10	27.78

Most common clinical features was fever (100%) followed by skin rashes (39%), vomiting (33%), respiratory symptoms (25%), CNS symptoms (25%), pain abdomen (22%), diarrhea (22%), and myalgia (14%). Headache, bleeding manifestations and edema were present in only four patients (11%). Joint pain was complained only by three patients (8.33%). Arthritis was not present in any case. Skin manifestations were in form of erythematous maculopapular lesion in eight patients (22%) followed vesiculobullous lesion in 3 (8.33%) patient and hyperpigmented rashes in three (8.33%). All three patients with vesiculobullous lesions were infants. CNS manifestations were in the form of seizure in 5 (13.89%) patients and altered sensorium in 4 (11%) patients. Bleeding manifestations were in form of hematuria (3 cases), and epistaxis (2 cases). Skin manifestations were the most common presentation apart from fever in less than 12 months of age group followed by diarrhea and respiratory symptoms (cough, coryza). (Table 2)

Table 2
Clinical presentation of Study Population (N=36)

S. No.	Bio-demographic Variable	Number	Percentage (%)
1	Fever	36	100
2	Skin rash	14	38.9
3	Vomiting	12	33.3
4	CNS symptoms	9	25
5	Cough/ corrhyza	9	29
6	Pain abdomen	8	22.2
7	Diarrhea	8	22.2
8	Headache	4	11.1
9	Bleeding manifestations	4	11.1
10	Edema	4	11.1
11	Arthralgia	3	8.33

Among the laboratory investigations, thrombocytopenia was the most common finding presented in 14 patients (39%). In these patients platelets were ranging from 21,000 to 112,000 cells/mm³. Thrombocytosis was present in five patients (maximum up to 829,000 cells/mm³), leucocytosis in four and leucopenia in three patients. Liver enzymes (SGOT/SGPT) were deranged in 13 patients (36%). Ten patients had mild elevation (<3times) and three patient had moderate elevations (maximum upto SGPT 743 u/l) of liver enzymes (3 to 10 times). Blood urea was high in 4 patients (maximum upto 112 mg/dl). Serum creatinine was normal in all patients. (Figure 1)

Figure 1

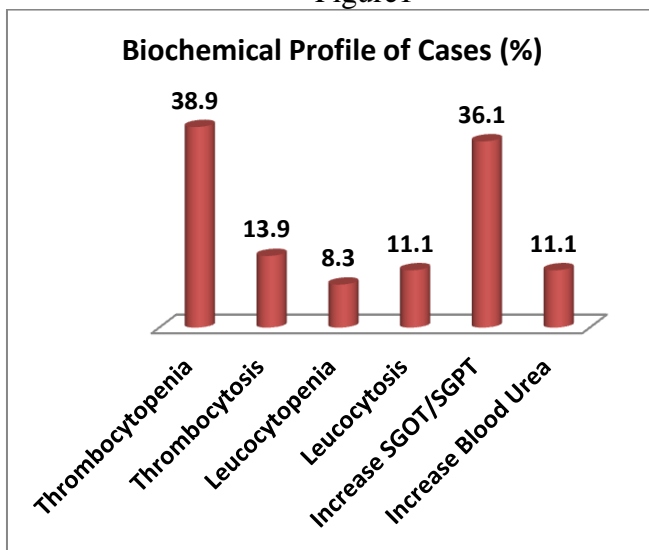
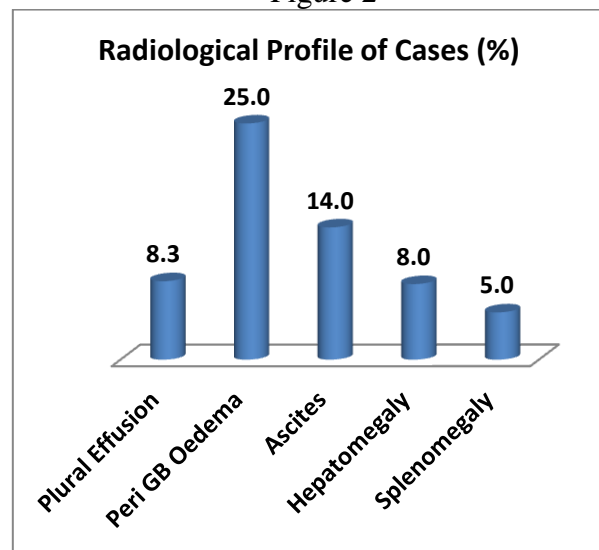


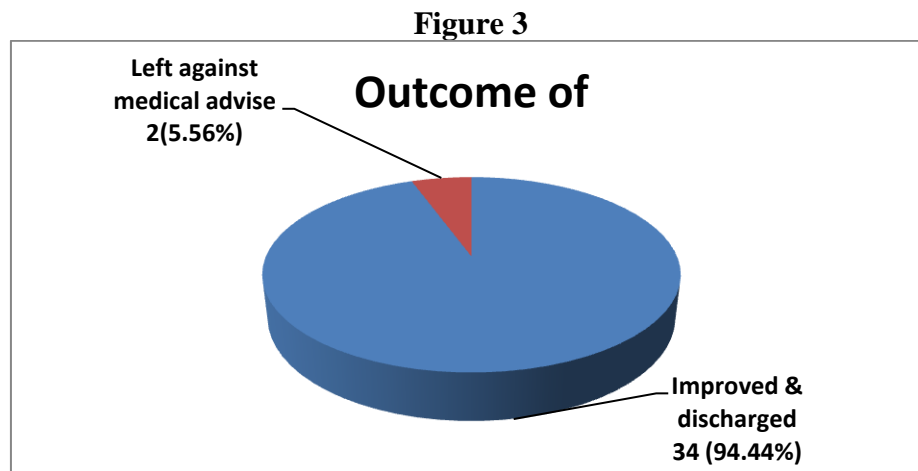
Figure 2



Chest-X-ray PA view and ultrasound abdomen were done for all children. Pleural effusion was present in 3 cases. Ultrasound abdomen showed peri gall bladder edema in 25% patients, ascites in 14%, hepatomegaly in 8%, and splenomegaly in 5%. (Figure 2)

CSF study was normal in all 9 patients presenting with seizure and altered sensorium. Out of those MRI brain was conducted in five patients, which showed grossly no abnormality in four patients. One patient showed feature suggestive of meningoencephalitis.

The average duration of hospital stay was 5.1 days (range 3 to 9 days). Out of 36 chikungunya patients, 34 were improved and discharged in satisfactory condition with no residual sequelae and 2 patients though improving voluntarily left against medical advice. (Figure 3)



IV. DISCUSSION

The chikungunya epidemic epitomizes the classic interaction between agent, host and environment.^{3, 5} Children are among the group at maximum risk for severe manifestations of the disease and some clinical features in this group are distinct from those seen in adults.⁶ Following transmission, chikungunya replicates in the skin, and disseminates to the liver, muscle, joints, lymphoid tissue (lymph nodes and spleen) and brain, presumably through the blood. Typically, joint damage fluctuates over time, but always affects the same parts of the body, mostly the extremities (hands, ankles, knuckles).⁵⁻⁸

After a median incubation period of 2 to 4 days (range: 2 to 12 days) the disease manifests, without prodrome, with the prototypical features of fever, rash and arthralgia. In most of the cases the disease is self-limiting and the symptoms disappear within 5 to 7 days even without treatment. Rarely the symptoms may persist for a longer period and occasionally complications may develop.⁵

The recent resurgence of chikungunya fever has drawn global attention due to its explosive onset, rapid spread, high morbidity, and myriad clinical manifestations. Till 11th September, 2016 a total of 14656 clinically suspected cases (including 1724 in Delhi) from 18 states and 2 Union Territories have been reported.³

Majority of the patients of chikungunya present with fever, arthralgia, arthritis, and mucocutaneous manifestations. Chronic arthritis may develop in about 15% of the adult patients. The chikungunya viral polyarthropathy frequently involves the small joints of the hand, wrist, and ankles and the larger joints such as knee and shoulder; more than 10 joint groups may be involved.^{3, 5} Usually the joint pain is severe enough to immobilize the patient and interfere with sleeping in the night. Joint pain may worsen with movement and back ache may also be present. We observed that joint manifestations were rarely seen, except mild joint pain in 3 patients in our study. Radiological joint findings are usually normal, and biological markers of inflammation may be normal or moderately elevated. Joint manifestations are less common in children in comparison to adults; residual arthralgia is also far less frequent in children.² Similar findings were noted in those three patients.

Skin lesions are commonly present in chikungunya, common skin lesion are generalized erythema, maculopapular rash, vesiculobullous lesions, epidermolysis bullosa and pigmentary changes.^{2,9} In presented study 39% patients had skin manifestations. Valampampil et al.⁷ studied clinical features in 56 chikungunya confirmed infants. These were having fever, seizures, loose stools, peripheral cyanosis and dermatological manifestations like generalized erythema, maculopapular rash, vesiculobullous lesions and skin peeling. They observed that at least one skin manifestation was present in all the infants and two or more manifestations were seen in 44% of infants. We noticed that all patients with vesiculobullous lesion were infants.

Inamadar et. al.⁹ reported cutaneous manifestations of chikungunya fever in an outbreak of chikungunya in Karnataka in 145 patients of all age groups. The most common dermatological manifestation was pigmentary changes (42%) in the form of an asymptomatic, brown- black pigmentation involving the centropacial area. Besides this, other pigmentary changes noted included freckle like macules, slate grey pigmentation of the face, pinna, and extremities. We also noticed 21% of dermatological manifestations as pigmentary changes. They also reported that presence of vesiculobullous lesions were exclusively confined to infants.⁹ In chikungunya affected children of the Reunion islands, epidermolysis bullosa has also been reported by Ernould S et al.¹⁰

Alpha viruses are known to cause devastating encephalitis. However neurological manifestations are not common with chikungunya.⁶ Neurological manifestations ranging from non specific symptoms to encephalitis may be seen. Suryawanshi et al.¹¹ conducted a study found that neurological manifestations were seen in 8 cases (9.2 %), encephalitis in 6 (6.9%) and transverse myelitis in 2 (2.2%). They conducted CT in five cases of encephalitis of which three did not show any abnormality, two had diffuse cerebral oedema. In our study 11% patients presented with altered sensorium. We found changes of meningoencephalitis in MRI of one patient.

Study conducted by Alladi Mohan et al.⁵ and Valampampil et al.⁷ found that febrile convulsions may occur in children with chikungunya. Simple and complex febrile seizures were observed in 17% children in our study. Lumbar puncture and CSF study was done in all of them with seizures. The CSF study results were normal in all of them; similar findings were found in the study conducted by Valampampil et al.⁷

Ganesan et. al.¹² reported 2 cases of chikungunya encephalomyeloradiculitis with neuroimaging and 1 case with autopsy findings. Rarely children may have focal seizures and even transient paralysis following convulsions. Other neurological features reported include altered level of consciousness, blindness due to retrobulbar neuritis and acute flaccid paralysis.^{2,5,6}

Unlike dengue fever, hemorrhagic manifestations are uncommon in chikungunya fever. When present, they are mild and inform of epistaxis, bleeding from the gums, positive Hess test, subconjunctival bleed, and petechial/purpuric rash.⁵ Nimmannitya et. al.¹³ showed incidence of chikungunya in children with hemorrhagic fever was nearly 7.6%, while dengue accounted for nearly 83% of cases. Similar results were found in our study we came across 8.6% patients with bleeding manifestations.

Loose stools occurred in 22% children in our study. Valampampil et. al.⁷ found 41% infants presenting with diarrhea. Swaroop et. al.¹⁴ described the presence of acral edema in chikungunya infection in children. In our study we came across 3 patients (8.6%) with edema of lower extremities and one with generalized edema.

Hematological testing in chikungunya may reveal leukopenia with relative lymphocytosis by day 3 to 6 of the illness. Insignificant rise in hematocrit may occur by day 2 to 4 of the illness. Thrombocytopenia may occur but is not severe and bleeding manifestations often do not correlate with platelet counts particularly in infants.^{2, 5, 6} In our study 39% of patients had thrombocytopenia.

Chikungunya is a self limiting illness with recovery being the rule.² We also found that all children completely recovered without any residual sequelae at the time of discharge. In the present study, duration of hospital stay ranged from 3 to 9 days (mean 5.1 days). The mortality rate is low (0.4%), but is higher in babies less than 1 year old (2.8%) and increases in the elderly with concurrent diseases.¹⁵ Indiscriminate use of corticosteroids, nonsteroidal anti-inflammatory drugs especially aspirin, and antibiotics can contribute to thrombocytopenia, gastrointestinal bleeding, nausea, vomiting and gastritis. This may lead to dehydration, prerenal acute renal failure, dyselectrolytemia and sometimes hypoglycemia. These can indirectly contribute to the mortality due to chikungunya fever.^{2, 3} No deaths were noticed in the present study which may be due to the rational use of the above drugs and close monitoring of all children.

Out of 15 patients with co-infections, 9 were vector borne co-infection (dengue in 6 cases, scrub typhus in 3) for rest 6 cases it could not be ascertained that whether chikungunya increase the occurrence of secondary infections or it was a coexistent infection by chance. An interesting finding was noted with co-infections with chikungunya that bacterial sepsis and pyomeningitis were present in patient of less than 6 months of age. There are some limitations in our study, it was a cross-sectional retrospective study and data was collected from hospital records.

V. CONCLUSION

It was concluded from this present study that Clinical manifestations of chikungunya fever are different in children as compared to adults. Chronic sequelae of joint involvement are rare in this age group whereas skin manifestations are common. Prognosis and outcome in children is good. An entirely different spectrum of disease is seen in infants with chikungunya as compared to older children who need to be carefully observed.

CONFLICT OF INTEREST

None declared till now.

REFERENCES

- [1] Ross RW. The Newala epidemic. III. The virus: isolation, pathogenic properties and relationship to the epidemic. *J Hyg (Lond)*. 1956 Jun;54(2):177-91
- [2] Halstead SB. Chikungunya. In Feigin RD, Cherry JD, Demmler GJ, Kaplan SL (Eds). *Textbook of Pediatric Infectious Diseases*. Saunders; Philadelphia. 2004; 2178-2184
- [3] National guidelines for clinical management of Chikungunya 2016. Directorate of National Vector Borne Disease Control Programme, Ministry of Health and Family Welfare, Government of India. accessed from <https://nvbdc.gov.in/Doc/National-Guidelines-Clinical-Management-Chikungunya-2016.pdf> on 01/10/2016
- [4] Porterfield JS. Antigenic characteristics and classification of the togaviridae. In Schlesinger RW (Ed). *The Togaviruses: Biology, Structure, and Replication*. Academic Press; New York. 1980; 13-46
- [5] Alladi Mohan, DHN Kiran, I Chiranjeevi Manohar, D Prabath Kumar. Epidemiology, clinical manifestations, and diagnosis of chikungunya fever: lessons learned from the re-emerging epidemic. *Indian J Dermatol*. 2010 Jan-Mar; 55(1): 54-63.
- [6] Sebastian MR, Lodha R, Kabra SK. Chikungunya infection in children. *Indian J Pediatr*. 2009 Feb;76(2):185-9.

- [7] Valampampil JJ, Chirakkarot S, Letha S, Jayakumar C, Gopinathan KM. Clinical profile of Chikungunya in infants. *Indian J Pediatr.* 2009 Feb;76(2):151-5
- [8] Kalantri SP, Joshi R, Riley LW. Chikungunya epidemic: an Indian perspective. *Natl Med J India.* 2006 Nov-Dec;19(6):315-22
- [9] Inamadar AC, Palit A, Sampagavi VV, Raghunath S, Deshmukh NS. Cutaneous manifestations of chikungunya fever: observations made during a recent outbreak in south India. *Int J Dermatol.* 2008 Feb;47(2):154-9
- [10] Ernould S, Walters H, Alessandri JL, Llanas B, Jaffar MC, Robin S, Attali T, Ramful D, Combes JC. Chikungunya in paediatrics: epidemic of 2005-2006 in Saint-Denis, Reunion Island. *Arch Pediatr.* 2008 Mar;15(3):253-62
- [11] Suryawanshi SD, Dube AH, Khadse RK, Jalgaonkar SV, Sathe PS, Zawar SD, Holay MP. Clinical profile of chikungunya fever in patients in a tertiary care centre in Maharashtra, India. *Indian J Med Res.* 2009 Apr;129(4):438-41
- [12] Ganesan K, Diwan A, Shankar SK, Desai SB, Sainani GS, Katrak SM. Chikungunya encephalomyeloradiculitis: report of 2 cases with neuroimaging and 1 case with autopsy findings. *AJNR Am J Neuroradiol.* 2008 Oct;29(9):1636-7. doi: 10.3174/ajnr.A1133
- [13] Nimmannitya S, Halstead SB, Cohen SN, Margiotta MR. Dengue and chikungunya virus infection in man in Thailand, 1962-1964. I. Observations on hospitalized patients with hemorrhagic fever. *Am J Trop Med Hyg.* 1969 Nov;18(6):954-71
- [14] Swaroop A, Jain A, Kumhar M, Parihar N, Jain S. Chikungunya fever. *Journal, Indian Academy of Clinical Medicine.* 2007;8(2):164-168
- [15] Nagpal BN, Saxena R, Srivastava A, Singh N, Ghosh SK, Sharma SK et al. Retrospective study of chikungunya outbreak in urban areas of India. *Indian J Med Res.* 2012 Mar;135:351-8