

Variation in origin of Lateral Circumflex Femoral Artery: A Case Report

Dr. Somya^{1*}, Dr. Seema Gupta², Dr. Sangita Chauhan³

¹Resident, Department of Anatomy, S.M.S Medical College, Jaipur(Rajasthan)India

²Professor, Department of Anatomy, S.M.S Medical College, Jaipur(Rajasthan)India

³Senior Professor, Department of Anatomy, S.M.S Medical College, Jaipur(Rajasthan)India

Abstract— *Profunda femoris artery and its branches are extensively used in different diagnostic and therapeutic interventions. Knowledge about the anatomical variations is important to prevent iatrogenic complications. During routine dissection for teaching medical graduates, a variant vascular pattern of lateral circumflex femoral arteries was observed in an adult cadaver. The Lateral Circumflex Femoral Artery was found to be arising directly from the Femoral Artery on its posterior aspect, 7.0 cm distal to the inguinal ligament on the left side.*

Keywords: *Profunda Femoris Artery, Lateral Circumflex Femoral Artery, Femoral Artery.*

I. INTRODUCTION

Lateral circumflex femoral artery is a branch of Profunda femoris artery. It arises from lateral aspect of the upper end of the Profunda femoris artery in the femoral triangle. It passes between the division of femoral nerve and divides into ascending, transverse and descending branches. It is an important artery in supplying blood to the head and neck of the femur and to fatty tissue in the acetabular fossa.

Lateral circumflex femoral artery gives branches for trochanteric anastomosis (ascending branch), cruciate anastomosis (Descending branch) and anastomosis around the knee joint (a twig from descending branch).¹ Anatomy of lateral circumflex femoral artery is very important for plastic surgeons as vascular flaps containing these vessels such as antero-lateral thigh flaps and the tensor-fascialata-myocutaneous flaps can be used as a graft for various reconstructive surgeries of large tissue loss in the head and neck region, aorto-popliteal bypass, coronary artery bypass grafting, and extra-cranial intracranial bypass surgery and for patients undergoing orthopedic surgery of the lower extremity.²⁻⁷

Therefore, the knowledge of variation of this artery is important for anaesthetists during femoral nerve blockade and also during procedures in the femoral region and hip joint replacements for avoiding iatrogenic vascular necrosis of the head of femur during reconstructive surgery of the hip joint.⁸ This report presents a case of variation in the origin of Lateral Circumflex Femoral Artery.

II. METHODOLOGY

A rare variation in the origin of Lateral Circumflex Femoral Artery was observed in Anatomy Department of SMS Medical College, Jaipur (Rajasthan) India. So case study was done thoroughly and case report was prepared to publish this rare case.

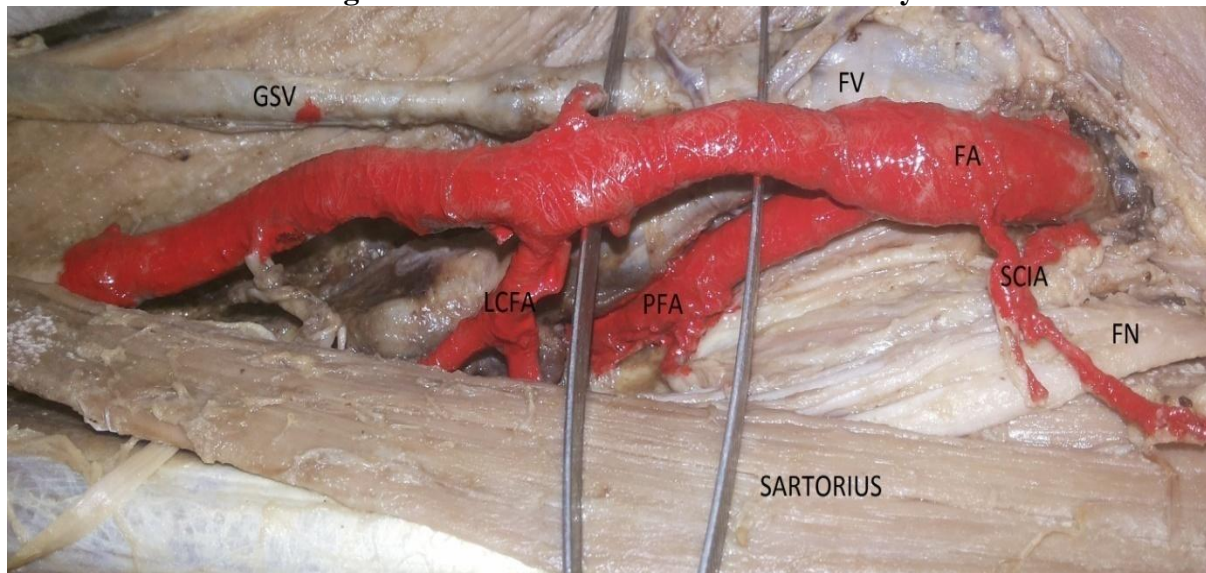
III. CASE REPORT

In the present case, during routine dissection of lower limb in the Department of Anatomy, S.M.S Medical College, Jaipur, a variant vascular pattern was observed in a middle aged male cadaver on the left limb. On the left limb the profunda femoris artery branched from medial side of femoral artery just

beneath the inguinal ligament and coursed down behind the femoral vein and terminated as usual. On its course it gave all the branches except lateral circumflex femoral artery.

Lateral Circumflex Femoral Artery was found to be arising directly from the Femoral Artery on its posterior aspect; 7.0 cm distal to the inguinal ligament on the left side and further branched into ascending, transverse and descending branches. Medial circumflex femoral artery branched out from medial side of profunda femoris artery which coursed behind the femoral vessels. (Figure 1)

Figure 1
Origin of Lateral Circumflex Femoral Artery



FA - Femoral Artery, FN - Femoral Nerve, FV - Femoral Vein, PFA - Profunda Femoris Artery, LCFA- Lateral Circumflex Femoral Artery, GSV-Great Saphenous Vein

IV. DISCUSSION

Lateral circumflex femoral artery and its branches are used in various bypass surgeries in iliofemoral region as well as in cranial cavity, as LCFA is big and carry significant amount of blood to the femoral neck, muscles and skin over the thigh so the blood supply is more and there will be less chances of flap necrosis.⁹

Many previous studies have reported variation in origin of lateral circumflex femoral artery. Hollinshead reported that the lateral circumflex femoral artery arises from the femoral artery in 15% of cases proximal to the Profunda femoris artery.¹⁰ Uzel M et al studied 110 inguinal regions and found lateral circumflex femoral artery arising from Profunda femoris artery in 85 cases (77.3%) and from femoral artery including common stem in 25 cases (22.7%).

Bergman RA et al (1996) observed 200 limbs out of which in 123 cases both the lateral and medial circumflex femoral arteries originated from Profunda femoris artery. Lateral circumflex femoral artery was arising from femoral artery in 29 cases.¹² Tanyeli et al. reported the origin of the lateral circumflex femoral artery from the femoral artery distal to the profunda femoris artery .¹¹

Dixit D et al observed the origin of lateral circumflex femoral artery on the right side was from profunda femoris artery in 72.8% (83 cases), from femoral artery as a common stem with profunda femoris artery in 17.5% (20 cases), from femoral artery superior to profunda femoris artery in 5.2% (6 cases), from femoral artery inferior to profunda femoris artery in 2.6% (3 cases).¹³

Baptist et al. have reported the origin of lateral circumflex femoral artery from femoral artery.¹⁴ Prakash et al. concluded that the circumflex branches of profunda femoris artery branched directly from femoral artery when it was associated with lower level of separation of the profunda femoris artery from the femoral artery.¹⁵

In yet another study done in 224 femoral triangles around 39% of cases profunda femoris artery was found to arise either from medial or posterior aspect of femoral artery. Out of that 5 cases profunda femoris artery was coursing superficial to femoral artery.¹⁶ In a study done in Indian population, two out of 64 extremities (3.1%) reported profunda femoris artery came from medial side of femoral artery.¹⁷ Other similar cadaveric studies the occurrence were reported as 16.6%, 13.2% and 43.33%, respectively.¹⁸⁻²⁰ Bilateral origin of lateral circumflex femoral artery from the femoral artery has also been reported.²¹

V. CONCLUSION

The anatomical knowledge of the variations of the lateral circumflex artery is significant when undertaking clinical procedures in the femoral region and hip joint replacements, in vascular reconstructive procedures, in catheterization procedures, in surgical interventions for embolism, and in raising myocutaneous grafts with pedicles. It also helps in reducing the chances of intra-operative secondary haemorrhage and post-operative complications. Such variation should be reported to determine the exact prevalence of the variation in site of origin of lateral circumflex femoral artery.

CONFLICT OF INTEREST

None declared till now.

REFERENCES

- [1] Mahadevan V. Pelvic girdle, gluteal region and thigh. In: Standring S, eds. Gray's Anatomy, The Anatomical Basis of Clinical Practice. 40th ed. India: Elsevier; 2008: 1378-1379.
- [2] Fernandes R, Lee J. Use of the lateral circumflex femoral artery perforator flap in the reconstruction of gunshot wounds to the face. *J Oral Maxillofac Surg.* 2007;65(10):1990-7.
- [3] Valdatta L, Tuinder S, Buoro M, Thione A, Faga A, Putz R. Lateral circumflex femoral arterial system and perforators of the anterolateral thigh flap: an anatomic study. *Ann Plast Surg.* 2002;49:145-50.
- [4] Gradman WS. Bypass to the lateral circumflex femoral artery. *Ann Vasc Surg.* 1992;6:344-6.
- [5] Sugawara Y, Sato O, Miyata T, Kimura H, Namba T, Makuuchi M. Utilization of the lateral circumflex femoral artery as a midway outflow for aortopopliteal grafting: report of a case. *Surg Today.* 1998;28:967-70.
- [6] Fukuda H, Ashida M, Ishii R, Abe S, Ibukuro. Anatomical variants of the lateral femoral circumflex artery: an angiographic study. *Surg Radiol Anat.* 2005;27:260-4.
- [7] Başkaya MK, Kiehn MW, Ahmed AS, Ateş Ö, Niemann DB. Alternative vascular graft for extracranial-intracranial bypass surgery: descending branch of the lateral circumflex femoral artery. *Neurosurg Focus.* 2008;24:1-7.
- [8] Asharani SK, Kuberappa V. Variation in the origin of Lateral circumflex femoral artery. *International Journal of recent trends in science and technology.* 2014;12(3):420-22.
- [9] Standring S. Gray's anatomy. The Anatomical Basis of the Clinical Practice. 40th edition, Spain: Churchill Livingstone Elsevier. 2008;1380.
- [10] Shetty AS, Shetty S, Rakesh G, Pamidi N, Jetty R. An atypical oversized lateral circumflex femoral artery and its clinical implications. *JCDR.* 2012;6(7): 1284-85.
- [11] Hollinshead HW. Textbook of Anatomy. 3rd Ed., Hagerstown, Maryland, Harper & Row. 1974; 407. Uzel M, Tanyeli E, Yildirim M. Anatomical study of the origin of lateral circumflex femoral artery in Turkish population. *Folia Morphol (Warsz)* 2008;67(4):226-230.
- [12] Bergman RA, Afifi AK, Miyayichi R. Compendium of Human Anatomic variations: Urban & Schwarzenberg. Baltimore -Munich 1988; 86-87.

- [13] Dixit D, Kubavat DM, Rathod SP, Pateld MM, Singel TC. A study of variations in the origin of profunda femoris artery and its circumflex branches. *Int J Biol Med Res*, 2011;2:1084–1089.
- [14] Baptist M, Hussain T, Sultana F. The origin of Profunda femoris artery, its branches and diameter of the femoral artery. *Professional Med J*. 2007; 14: 523–527.
- [15] Prakash, Jyoti K, Bhardwaj AK, Jose BA, Yadav SK, Singh G. Variations in the origins of the Profunda femoris, medial and lateral femoral circumflex arteries: a cadaveric study in Indian population. *Rom J Morphol Embryo* 2010;51:167-70.
- [16] Dixit D, Kubavat DM, Rathod SP, Pateld MM, Singel TC. A study of variations in the origin of profunda femoris artery and its circumflex branches. *Int J Biol Med Res*. 2011; 2: 1084–1089.
- [17] Prakash, Kumari J, Kumar Bhardwaj A, Jose BA, Kumar Yadav S, Singh G. Variations in the origins of the profunda femoris, medial and lateral femoral circumflex arteries: a cadaver study in the Indian population. *Rom J Morphol Embryol*. 2010; 51: 167–170.
- [18] Dixit DP, Mehta LA, Kothari ML. Variations in the origin and course of profunda femoris. *J Anat Soc India*. 2001; 50: 6–7.
- [19] Choi SW, Park JY, Hur MS, Park HD, Kang HJ, Hu KS, Kim HJ. An anatomic assessment on perforators of the lateral circumflex femoral artery for anterolateral thigh flap. *J Craniofac Surg*. 2007; 18: 866–871.
- [20] Tansatit T, Wanidchaploi S, Sanguansit P. The anatomy of the lateral circumflex femoral artery in the anterolateral thigh flap. *J Med Assoc Thai*. 2008; 91: 1404–1409.
- [21] Balachandra N, Prakash BS, Padmalatha K, Ramesh BR. Variation in the origin of the lateral circumflex femoral artery – a case report. *Anatomica Karnataka*. 2011; 5: 76–80.