

A Descriptive Study of Differentially Placed Hydatid cysts

Giorgio Maria Paul Graziano¹, Rinzivillo C², Prof. Antonino Graziano^{3s}

¹Department of Sciences Medical Surgery and advanced technologies, University of Catania Medical School, Italy

²MD, Department of Sciences Medical Surgery and advanced technologies, University of Catania Medical School, Italy

³Professor, Department of Sciences Medical Surgery and advanced Technologies University of Catania Medical School, Italy

Abstract—*In Italy the hydatid disease is more prevalent and new cases are highlighted more frequently in Sicily, Sardinia, (Italy). Aim of this study is to put the indication in search of iaditea nature in both spleen swelling and muscle tendon.*

Material and Method *Patients observed during the period 2007-2009 at the Surgical Clinic III and Digestive Surgery, Policlinico G Rodolico were explored for Hydatid cyste at various sites. Diagnosis of cysts ecchinococcus occurred primarily for various four reasons either for compression of bodies involved or for eosinophilia or for instrumental investigation or for anaphylactic reaction to rupture of cysts. Biological diagnosis is based on serology rather than isolation of the parasite (indirect diagnosis);*

Results *Patients attended during the period 2007-2009 Hydatid cyst was found in 0.5% of all cases in liver along with 4 in the lung, 3 in splenic, 2 in the mammary and 2 in the chest wall No 2. The Surgical treatment with the complete removal of the cyst with a satisfactory postoperative course in the absence of cases of relapse of the disease and by following the therapeutic act, the assumption of mebendazole 50mg / kg / day for 3 weeks at a dose of 400mg for 4 months*

Conclusions *There is a need to define diagnostic methods with high specificity and sensitivity, which can provide a valid diagnostic aid for the cases clinically difficult to diagnose. And the final diagnosis must then also be based on the development of immunological methods that allow the determination of specific antibodies in the serum and their titration and / or the circulating antigen determination.*

Key words: *Cyst Excision Monoclonal Antibodies*

I. INTRODUCTION

In Italy, hydatid disease has a high incidence and new cases are highlighted more frequently in Sicily, Sardinia (Italy).^{1,2,3} In the percentages of the different locations the lung occupies 25% of the cases follow the nervous system, heart, bones, muscles and organs or organ systems that is well vascularized. The only way of spread of parasite in human is through digestive system and sometime rarely it can be inhaled. It travel mainly through intestinal wall but may transit though lacteal fluid, thoracic duct, the right heart and its capillaries to lung. Or from veins specially from portal vein is passed to systemic circulation. The purpose of this study is to present the most unusual locations of hydatid cyst placing an indication that in both spleens swelling that muscle tendon difficult clinical diagnosis. This can be echinococcus nature and in relation to our experience, the need to define new diagnostic methods with high specificity and sensitivity can be a great help in the diagnosis.

II. METHODOLOGY

A cross-sectional hospital based observational study was conducted on patients attended during the period 2007-2009 at the Third Surgical Clinic and Surgery of 'digestive system of the Hospital G Rodolico.

The diagnosis was strictly dependent on the location and evolution of the cyst; the slow development of the latter, determined the phase of asymptomatic, as in most of the cysts cases were in an early stage of disease. the diagnosis of cysts echinococcus occurred primarily for four reasons: 1) compression of bodies involved; 2) eosinophilia; 3) instrumental investigation (X-ray, ultrasound, CT); 4) anaphylactic reaction to rupture of cysts (2). However, imaging studies were not always conclusive, since the cysts, sometimes can have an atypical appearance that does not allow to differentiate them from abscesses or tumors and often are required serologic methods (1) Since then one of the few parasitic diseases which diagnosis organic is based on serology rather than isolation of the parasite (diagnostic indirect); The detection then the circulating antigens does not seem to be useful for diagnostic purposes (1). In relation to both the unusual home it found that the serology based on the detection of the antigen that does not allow in such cases to obtain a differential diagnosis related to the headquarters atypical lesion. Everything has stimulated to deepen research methodologies serological aimed at detecting early of the disease

Statistical Analysis: Univariate descriptive statistics included the frequency of distributions for categorical demographic variables.

III. RESULTS

In this study, Hydatid cyst disease was found in 0.5% of all cases in liver (Figure 3) along with 4 in the lung (Figure 2), 3 in splenic, 2 in the mammary (Figure 1) and 2 in the chest wall No 2. These patients were observed in the clinic and reported a gradual emergence of swelling on the dorsum near the armpit in the absence of pain, swelling with presence of elastic hard consistency fixed to the floors below with preserved. In others acute cases the symptoms were absent. In the remaining cases the localization was in the liver.(Figure 3)

Figure 1
Breast Cyst

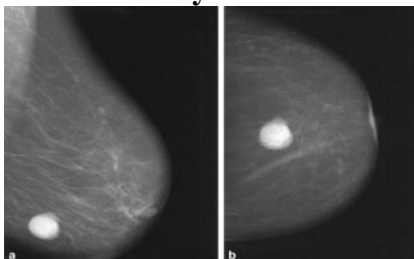


Figure 2
CT Lung Cyst

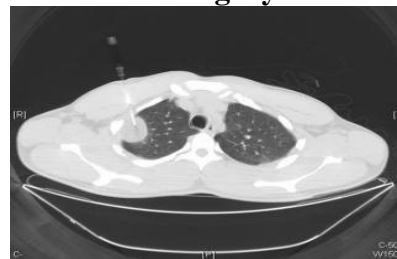
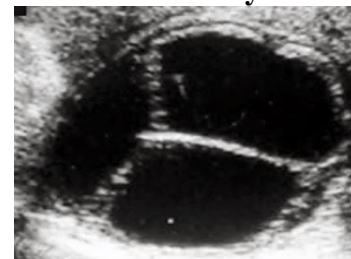


Figure 3
Eco Liver Cyst



Surgical treatment with excision of the cyst. affected all patients, with a satisfactory postoperative course in the absence of cases of disease recurrence and followed by the therapeutic act, with taking mebendazole 50mg / kg / day for 3 weeks at a dose of 400 mg for 4 months (3) postoperatively. We had also observed the absence of recurrence of the disease in a follow-up to 48 months. Exams diagnosticians (CT and MRI and serological) not allowed to obtain a clear diagnosis in a typical sites of disease. So we felt it was important both as a prevention program that as research, knowledge of the genotypes for us become a prerequisite for the targeted control to limit the transmission of *E. granulosus* in endemic regions like ours to break the cycles of transmission, You need to know the genotypes are present in a given area and which affect guests; the application of molecular techniques to characterize the parasites has made an important contribution to expand epidemiological knowledge.⁴ The cyst fluid consisting of glucose and lipoproteins, carbohydrates and salts, was the main source antigenic lipoprotein, the 'B antigen (AGB) and' antigen 5 (Bg5) are the major components of the cystic fluid and

are widely used for ' immune diagnosis of EC. ⁵ (6). The analysis of DNA, thanks to its high sensitivity, has provided very useful elements for discriminating the different genotypes. ⁶ (8) .This variability detected by analysis of mitochondrial DNA (mtDNA) was used to discriminate closely related organisms or by the ribosomal DNA (rDNA) for the study of genetic heterogeneity. The results obtained with the immune diagnosis in a first phase, were directed to the control of patients after surgical treatment and pharmacological. the antibody response varied in relation to the seat, and sizes, activities of the cyst, the cyst was absent if inactive, positive in a first step if cysts was active, and then becomes negative after three months on average to complete treatment.

IV. DISCUSSION:

L 'Cystic Echinococcosis in humans: clinical aspects of infection presents slow growth is almost always asymptomatic, and can take several years to reach a size that can cause major symptomatic manifestations. The nature and intensity of the clinical manifestations depend on the number of cysts present, of their location with low incidence in muscle site due to an unfavorable development of the parasite in its evolution. In some cases, in fact, hydatid cysts regress spontaneously with partial o reabsorption or calcification. the cysts may become symptomatic after the rupture of the cyst wall or for compressive action of the cyst in the growth, or, as a result of bacterial contamination, with transformation into an abscess The sudden rupture due to the secondary dissemination of protoscolices (secondary hydatid disease; also as a complication surgery) with the occurrence of hypersensitivity reactions (for release into the body of the parasite antigens that have a high power immune gen). We can thus eosinophilia, hives, itching, wheezing, asthma attacks up to anaphylactic shock.⁴ More than 90% of the cysts are localized in the liver and / or in both lungs; are reported occasionally (2-3%) in the kidney, spleen, into the peritoneal cavity, muscles and rarely (1%) in the heart, brain, spine, ovaries.⁷ The living conditions improving as well as increased vigilance health has revealed a decrease of more than 2% of detections in our series .the complications due to rupture of the cysts are: cholangitis and liver obstruction by daughter cysts in the bile ducts, bronchitis, pulmonary, cardiac embolism. The presence of cysts in bone fractures and often determines the localization in brain cysts occur with focal neurological deficits or signs of increased intracranial pressure. Cystic lesions can be of unspecified nature (CL), active (CE1, CE2) and inactive (CE4, CE5) ⁸ (16) and the immune diagnosis is useful not only for early diagnosis, but also to monitor patients after surgery and / or drug. ⁹ (12). The choice of a serological technique depends on its sensitivity and specificity. The method for the detection of circulating antigens was far less sensitive than that for the detection of antibodies, which remains the method of choice. The ELISA, indirect hemagglutination (IHA) and immune blotting are the most used immunological methods. ¹⁰ (13). Tests such as the reaction of Casoni, intradermal injection of antigenic determinants of *E. granulosus*, have now only a historical value. In recent years, many more reliable tests have been put into business. Il Boyden test based on an indirect hemagglutination (IHA, Indirect Hemo Agglutination) is one of the most common tests and used both for the simplicity of execution and for the relatively low cost ; It is characterized by a satisfactory specificity but with a not very high sensitivity. ^{11,12} (15.15). However, there are considerable difficulties in the use of these antigens related to standardization issues of their use and their low specificity and sensitivity. Often, in fact, we will have false positives in the course of malignancies or liver cirrhosis or false negative in the case of recent cysts (CE1) or involution stage (CE4-5). O with antigens from other parasites, in particular of other tapeworms. Currently, however, there is no very specific standardized method usable for the detection

of antibodies in cases of overt disease.⁸ (16). Antibody response, in fact, varies according to the characteristics of hydatid cysts such as the location (more intense in the liver and bone cysts than brain or spleen where a negative status) can also have, vitality (fertile cysts are accompanied by a response immune stronger than that of sterile cysts, senescent or calcified) and integrity (intact cysts are less immunogenic of cracked cysts) .I serological methods used to follow the post surgical phase or post drug, they are instead faces looking IgG4 , IgE and IgM antibody as these classes tend to disappear after an effective therapy. An innovative approach is based on the dose interleukin 4 in the serum; in fact, this cytokine tends to be reduced if the level of treatment undertaken was efficient.¹³ (17). In recent years, for diagnostic purposes, they were produced recombinant proteins diagnostic peptides able to increase test sensitivity and specificity.¹⁴ (18). However, the use of recombinant components has led in some cases to a lowering of the diagnostic sensitivity¹⁴ (18). Currently Serological diagnosis is obtained with the diagnostic tests using antigens purified, or partially purified, obtained from sheep cyst fluid. the need for an improvement in the diagnosis is strongly felt both for the presence of false negative (10-30%), patients with cysts very young subjects (initial stage) or calcified (final stage) for which is required a high sensitivity, both for the presence of patients, false positive (20 -40%), or patients residing in geographical areas with high endemicity of other helminthiasis for which a high specificity of the techniques used is required. Another major problem is the lack of international standardization of technical and antigens used in laboratories .In the present work were technical proteomic analysis used aimed at the characterization of the peptide and protein fraction of the cystic fluid. Using such techniques have been characterized, in the cystic fluid from sheep, the major protein secreted by the parasite can stimulate the human immune system.

V. CONCLUSIONS

This study conclude that hydatid cysts may be found at unusual places So there is a need to define diagnostic methods with high specificity and sensitivity, which can provide a valid diagnostic aid for the cases clinically difficult to assess, it passes through L 'utilization of a serological test of screening and / or confirmation for a correct estimate the spread of an infection in a population, which cannot fail to know in detail. Final diagnosis must therefore be based also on the development of immunological methods that allow the determination of specific antibodies in serum and their titration and / or the circulating antigen determination.

CONFLICT

None declared till date.

REFERENCES

- [1] Capron A., Vernes A., Biguet J., 1967. Le diagnostic immuno-electrophoretique de l'hydatidose. In: Le Kyste Hydatique du foie. SIMEP, Lyon, pp. 27-40.
- [2] Battelli G., 2004.Socio-economic impact of cystic echinococcosis and of its control; some data and consideration. *Parassitologia*; 46: 359-62.
- [3] Euzeby J., 1968. Larval echinococcosis, a major zoonosis. *Epidemiologic, etiologic and prophylactic study. Maroc Med.*; 48(518): 643-60
- [4] Cordero Del Campillo M., Rojo Vasquez F.A., Martinez Fernandez A.R., Sanchez Acedo M.C., Hernandez Rodriguez S., Navvarete Lopez-Cozar I., Diez Banos P., Quiroz Romero H., Carvalho Varala M., 1999. *Parasitologia veterinaria. McGraw-Hill Interamericana de Espana.*

- [5] Bauer C., Dausches A., Stoye M., 1986. Effect of a combination of fenbendazole and triclabendazole on naturally acquired helminth infections of sheep. *Dtsch Tierarztl Wochenschr.*; 93(9): 456-8.
- [6] Carmena D., Benito A., Eraso E., 2006. Antigens for the immunodiagnosis of *Echinococcus Granulosus* infection: an update. *Acta Tropica* 98: 74-86
- [7] Craig P.S.,McManus D.P., Lightowlers M.W., Chabalgoity J.A., Garcia H.H., Gavidia C.M., Gilman R.H., Gonzalez A.E., Lorca M., Naquira C., Nieto A., Schantz P.M., 2007.Prevention and control of cystic echinococcosis. *Lancet Infect Dis* 7: 385-394
- [8] In Eckert J., Gemmel M.A., Meslin F., Pawloski X.Z. (eds.), WHO/OIE Manual on Echinococcosis in humans and animals: A Public Health Problem of global concern. World Organization for animal health, Parigi:72-99
- [9] Craig P.S., Rogan M.T., Allan J.C., 1996. Detection, screening and community epidemiology of taeniid cestode zoonoses: cystic echinococcosis, alveolar echinococcosis and neurocysticercosis. *Adv Parasitol*; 38: 169-250.
- [10] Di Felice G., Pini C., Afferni C., Vicari G., 1986. Purification and partial characterization of the major antigen of *Echinococcus granulosus* (antigen 5) with monoclonal antibodies. *Mol. Biochem. Parasitol* 20: 107-13
- [11] Eckert J., Deplazes P., 2004. Biological, epidemiological, and clinical aspects of echinococcosis, a zoonosis of increasing concern. *Clin. Microbiol. Rev.* 17: 107-135.
- [12] Eckert J., Deplazes P., Traig P.S., Gemmel M.A., Gottstein B., Heath D., Jenkins D.J., Kamiya M., Lightowlers M., 2001. Echinococcosis in animals: clinical aspects, diagnosis and treatment.
- [13] Eckert J.; Thompson R.C., 1997. Intraspecific variation of *Echinococcus granulosus* and related species with emphasis on their infectivity to humans, *Acta Tropica*, Volume 64, Issue 1-2, April 1, Pages 19-34.
- [14] Graziano A e al (2006). retrovescical hydatidosis and renal failure. *POLICLINICO. SEZIONE CHIRURGICA*, vol. 113 n3, p. 90-93, ISSN: 0032-2636