

Submental Intubation Technique for Airway during Surgery of Midfacial and Panfacial Traumatic Injuries: A Descriptive Study

Dr Gds Kalra¹, Dr Kaustubh Shende*², Dr Jagdeep Rao³, Dr Amit Sharma⁴, Dr Ghisulal Chaudhari⁵, Dr Sunil Rathore⁶

¹MCH Plastic Surgery, Senior Professor and Head, Dept of Burns and Plastic Surgery, SMS Medical College, Jaipur, Rajasthan, India.

³MCH Plastic Surgery, Asst. Professor, Dept Of Burns And Plastic Surgery, SMS Medical College, Jaipur, Rajasthan, India.

^{2,4,5,6}MCH Plastic Surgery, Senior Resident, Dept of Burns and Plastic Surgery, SMS Medical College, Jaipur, Rajasthan, India.

Abstract—Submental intubation is a method for airway without trachiotomy. This study was conducted with the aim to evaluate the frequency, indications, and outcomes of airway management by submental intubation in maxillofacial trauma patients and comparison with tracheostomy regarding its advantages and disadvantages. 40 patients with maxillofacial injuries were selected for submental intubation who required tracheostomy/ retromolar intubation in a 2 year period (2013–2015). Submental intubation permitted reduction and fixation of all the fractures without the interference of the tube during surgical procedure in all of the patients. It avoids retromolar intubation/ tracheostomy and its disadvantages. Thus, Submental intubation is a simple, safe, with low morbidity technique for operative airway management in maxillofacial trauma patients when there are fractures involving the nasal region and concomitant dental occlusion disturbances who required retromolar intubation/ tracheostomy for airway management during surgery.

Key words: Submental Intubation, Tracheostomy, Maxillofacial Trauma Cases, Midfacial and Panfacial Traumatic Injuries

I. INTRODUCTION

It has been almost three decades since the submental intubation technique was first proposed by Hernández Altemir¹ for managing airway in complex maxillofacial injuries. The term transmylohyoid oroendotracheal intubation was first coined by Gadre and Kushte.^{2, 3} Road traffic accidents have been the most frequent cause of facial fractures. Studies in the last decade have shown that road traffic accidents are the most common cause of injuries in India.^{4,5} Securing an airway in complex maxillofacial injuries is always a challenging job for an anaesthetist and an oral and maxillofacial surgeon. The two most frequent route used to secure airway in these injuries are the oroendotracheal and the nasotracheal. Sometimes patients are also managed by tracheostomy.

Method of orotracheal intubation impedes any manoeuvres for reduction and stabilization of jaws and intermaxillary fixation. In most fractures, this is an essential guide to optimal fracture reduction and fixation.^{6,7}

In this study, patients of complex maxillofacial trauma in which this technique was employed avoiding a tracheotomy and result of this technique was observed and discussed.

II. METHODOLOGY

A hospital based descriptive study was conducted from August 2013 to July 2015 on patients underwent this technique avoiding a tracheostomy. For this study, multiple cranio-maxillofacial traumatic injuries cases who had tube interference with surgical intra-oral manipulation and maxilla-mandibular fixation were enrolled for study. Out of these enrolled cases those who required long-term airway management & maintenance and cases with severe neurologic damage or major thoracic trauma were excluded from study. Written informed consent for the procedure was obtained from all patients and one first degree relative. Cases who had not given written informed consent were also excluded from study. Total 40 cases of Multiple cranio-maxillofacial traumatic injuries were finally included in this study. The data recorded included the personal details of the patient, type of fractures sustained, duration of this technique and post-operative complications arising from this technique

2.1 Surgical technique

Orotracheal intubation was accomplished with flexo-metallic tube and the tube was secured temporarily with help of tissue plaster. Surgical skin preparation of the perioral and submental region was performed with chlorhexidine and povidone iodine and draped with sterile towels. Midline of face and chin was marked with skin marking pencil. The proposed line of incision in submental crease was marked, approximately 1-1.5 cm in length, or slightly greater than the diameter of tube. Surgical site was infiltrated with local anaesthetic solution containing 2% lignocaine with 1:100,000 adrenaline. Skin and subcutaneous connective tissue were incised in median submental region. The muscular layers, that is, platysma and mylohyoid muscles were traversed using curved artery forceps that was always kept in close contact with the lingual cortex of the mandible. Mouth was opened and tongue elevated in superio-posterior direction with tongue depressor, exposing ventral surface of tongue and floor of mouth. A strict midline plane was maintained. The curved artery forceps was then used to bluntly breach the mylohyoid muscle and force was readily passed into oral cavity using a palpating finger as a guide. With the curved haemostat, the tube cuff was passed extra-orally. Before disconnecting the ETT to the ventilator the patient was ventilated with 100% oxygen to increase apnoeic reserves and to prevent desaturation during the passage of the tube. The ETT is now disconnected; the universal connector being detached from the ETT, the pilot balloon is deflated and tucked inside the lumen of the ETT. Next the lumen of the ETT is grasped by artery forceps in a way that the ETT is not damaged and it is drawn out extra orally through the passage made. Once the ETT is out, the universal connector is reattached the tube is reconnected to the ventilator. Bilateral air entry was checked by auscultation and the tube is readjusted accordingly with the pilot cuff now being inflated with adequate air.

Tube was secured to the skin of submental region with 1.0 black silk suture. The proposed surgical procedure was accomplished. At termination of surgical procedure **endotracheal tube** (ETT) was extubated. The skin wound is closed by 3-0 nylon sutures while the intraoral wound was left to heal with secondary intention. The skin area is infiltrated by 0.5% bupivacaine to decrease post-operative discomfort and a pressure dressing is given on the skin.

2.2 Statistical Analysis

Data were summarized and analyzed with the help of MS Excel 2007 and statistical software Primer Version '6'. Descriptive analysis was done of various attributes of these cases.

III. RESULTS

Among total of 40 patients with multiple facial fractures underwent this procedure, 38 patients were male while 02 were females with age ranged from 18 to 70 years and were having an either one or a combination of leforte I, II, III, mandibular fractures, with nasal pyramid. (Table 1)

Table 1
Age and Sex wise Distribution of Study Population

	Parameters	No of patients	% of patients
1)	Age (in Years)		
	18- 30	26	65
	31- 40	8	20
	41- 50	3	7.5
	51- 60	1	2.5
	61- 70	2	5
2)	Sex		
	Male	38	95
	Female	2	5

Etiology of fractures in all patients was road traffic accidents. When fracture site was as observed it was found that 12 (30%) cases were having Panfacial fracture followed by LF-II + RT Zygoma (15%), NOE+LT MAXILLA (10%), B/L LF-III (10%), LF-II + LT Zygma (7.5%), B/L LF-II + Mandible (5%), LF-I+ Nasal Bone (5%), NOE+ LF-I(5%), NOE+RT MAXILLA(5%), RT Maxilla+ Mandible (5%) and Mandible + Nasal Bone (2.5%). (Table 2).

Table 2
Type of Fracture Site wise Distribution of Study Population

S. No.	Type of Fracture Site	No of patients	% of patients
1	Panfacial	12	30
2	LF-II + LT Zygma	3	7.5
3	LF-II + RT Zygoma	6	15
4	B/L LF-II + Mandible	2	5
5	LF-I+ Nasal Bone	2	5
6	NOE+ LF-I	2	5
7	NOE+LT MAXILLA	4	10
8	NOE+RT MAXILLA	2	5
9	RT Maxilla+ Mandible	2	5
10	B/L LF-III	4	10
11	Mandible + Nasal Bone	1	2.5

All patients were treated with open reduction and internal fixation for various fractures. Intra-operative maxillomandibular fixation was accomplished in all the cases. A good reduction and fixation was achieved in all patients. Mean time required for this procedure was 7.58 min and disconnection time of the ETT from the ventilator was less than 2.06 min which hardly affected the oxygen saturation of the patient as the patients were pre-oxygenated with 100% oxygen. There were no episodes of arterial desaturation while converting oral intubation to submental intubation and vice versa. Care was taken not to damage pilot balloon and ETT connector could be easily removed and reattached firmly.

During the procedure, one patient developed separate tract for tube and cuff in passing the tube through the floor of mouth. During extubation cuff was retrieved carefully through main tract, while one patient had damage to cuff which required change of tube. No intra-operative complication/ inconvenience was noted by surgeon or anaesthetist. (Figure 1&2)

All patients showed good postoperative healing . One patient developed post-operative bleeding and sublingual hematoma at submental wound during hospital stay which was managed immediately with control of bleeding from skin edge and drainage of hematoma. Eight patients developed post-operative pain and discomfort which was managed with appropriate analgesics. (Figure 1&2)

Patients were followed-up during hospital stay and after period of 3 months which showed undetectable scar in submental region. All fracture sites had healed well and excellent aesthetics were achieved. The submental scar was imperceptible in all patients except on close observation with neck hyper-extended. (Figure 1&2)

Figure 1

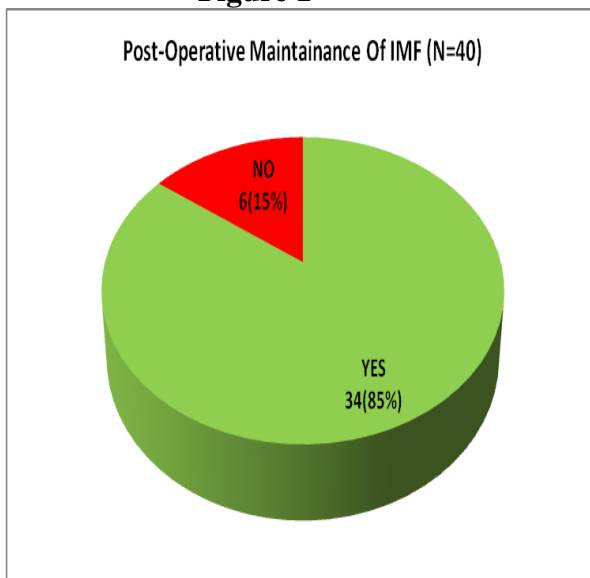
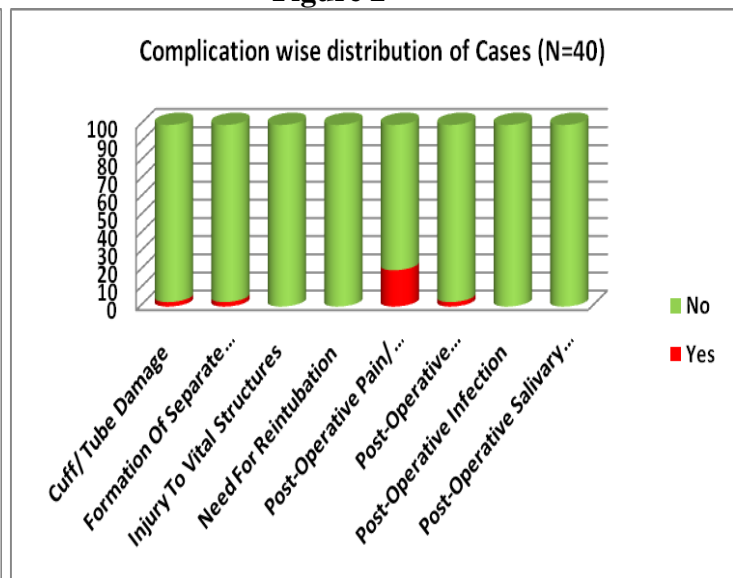


Figure 2



IV. DISCUSSION

In this study, all the 40 cases of panfacial trauma using submental intubation of which all were followed-up at the end of 3 months. All the cases healed without complications. Infection of submental wound was noted in one case postoperatively during hospital stay. The wound was cleaned twice a day with hydrogen peroxide and saline and then with betadine. The healing was achieved within 5-7 days.

The submental scarring in all the cases was imperceptible except upon close observation with neck hyper-extended. The intra-oral wound healed atraumatically in all the cases. All the patients were extubated in the immediate, postoperative period. Hence, the effects on long term airway support were not judged.

Several recent publications have dealt with the dangers of nasoendotracheal intubation in the presence of midfacial and basilar skull fractures.^{6,8} Lefort II and III facial fractures which involve the cribriform plates pose the greatest potential for untoward effects from nasoendotracheal intubation. Among the complications are cranial intubation, epistaxis, and trauma to the pharynx, pressure necrosis of the external nares, otitis media, and avulsion of turbinate bones, sepsis and inability to pass a tube through the nasal passage.^{6,7} Tracheostomy may be accompanied by severe morbidity such as infection, haemorrhage, subcutaneous emphysema, pneumothorax, pneumomediastinum, recurrent laryngeal nerve damage, tracheal stenosis, disruption of posterior tracheal wall and tracheoesophageal fistula^{6,9-11} blockage of tracheostomy cannula, tracheitis, cellulitis, pulmonary atelectasis, tracheocutaneous fistula, stomal and respiratory tract infection, tracheal stenosis, tracheal erosions, dysphagia, problems with decanulation, excessive scarring and requires careful surgical and perioperative management.¹²⁻¹⁴ Tracheostomy may also result in severe bleeding and cardiac arrest secondary to hypoxia. Mark stated that major operative bleeding occurs in approximately 5% of patients undergoing standard tracheostomy.¹¹

Advantages of sub-mental technique over tracheostomy like Early extubation after operation, Avoiding the cumbersome task of postoperative tracheostomy tube care and Avoidance of possible known complications of tracheostomy tube were reported in literature.¹⁵

A careful analysis of the anatomy of the anterior floor of the mouth indicated that, if a strict midline approach to submental intubation was adhered to, all major anatomical structures including Whartons duct, lingual nerves and sublingual glands could be avoided. Moreover, there is minimal vascularity in the midline as opposed to the hemorrhage encountered in the lateral sulcus approach.^{6,10} According to Gadre and Kushte remaining in contact with the lingual cortex of the mandible, the protection of lingual nerve, the submandibular duct, and mandibular branch of the facial nerve is guaranteed. Furthermore remaining anterior to the masseter muscle guarantees protection to the facial artery.³

As the passage of the tube is done in two stages (the tube cuff and then the tube itself) one must take care not to create two tracks. This would lead to difficulties in positioning the tube during the operation and to its blockage during extubation.¹⁶

According to the literature and observations of this study found that submental endotracheal intubation is a simple technique with low morbidity. The technique with no specialized equipment or technical expertise required gives unique advantage over other techniques to avoid tracheostomy. It combines the advantages of the nasotracheal intubation and orotracheal intubation by allowing access to the interdental occlusion and nasal pyramid, respectively. It presents a low incidence of operative and postoperative complications and eliminates the risks and side effects of tracheostomy. Thus, it can be used as an alternative to tracheostomy in selected cases of maxillofacial trauma, where nasotracheal and orotracheal intubation is impossible or contraindicated and long-term ventilation support is not required. As the tube is away from operative field it also avoids intra-operative disturbances to surgeon due to tube manipulations by anaesthetists. This helps to reduce chances of any breach in asepsis, furthermore reducing the risk of infection.

V. CONCLUSIONS

Hence, it is concluded that the submental intubation is a simple, safe, and alternative technique of intubation to tracheostomy in cases of maxillofacial trauma.

CONFLICT

None declared till date.

REFERENCES

1. Hernández Altemir F. The submental route for endotracheal intubation. A new technique. *J Maxillofac Surg* 1986;14:64-5.
2. Gadre KS, Kushte D. Transmylohyoid oroendotracheal intubation: A novel method. *J Craniofac Surg* 1992;3:39-40.
3. Gadre KS, Waknis PP. Transmylohyoid/submental intubation: Review, analysis, and refinements. *J Craniofac Surg* 2010;21:516-9.
4. Vincent RL, Shepherd JP. *Maxillofacial Injuries*. 2 nd ed., Vol. 2. Edinburgh: Churchill Livingstone; 1994. p. 1053.
5. Marya CM, Ashok K, Kottrashetti SM. Maxillofacial injuries and changing treatment modalities. *Indian J Oral Maxillofac Surg* 1997;12:25-28.
6. Gordon NC, Tolstunov L. Submental approach to oroendotracheal intubation in patients with midfacial fractures. *Oral Surg Oral Med Oral Pathol Oral Radiol Endod* 1995;79:269-72.
7. Green JD, Moore UJ. A modification of sub-mental intubation. *Br J Anaesth* 1996;77:789-91.
8. Zmyslowski WP, Maloney PL. Nasotracheal intubation in the presence of facial fractures. *JAMA* 1989;262:1327-8. [PUBMED]
9. Shenoj RS, Badjate SJ, Budhraj NJ. Submental orotracheal intubation: Our experience and review. *Ann Maxillofac Surg* 2011;1:37-41. [PUBMED]
10. Crysedale WS, Forte V. Posterior tracheal wall disruption: A rare complication of pediatric tracheotomy and bronchoscopy. *Laryngoscope* 1986;96:1279-82. [PUBMED]
11. Orringer MB. Endotracheal intubation and tracheostomy: Indications, techniques, and complications. *Surg Clin North Am* 1980;60:1447-64. [PUBMED]
12. Walker DG. Complications of tracheostomy: Their prevention and treatment. *J Oral Surg* 1973;31:480-2.
13. Stauffer JL, Olson DE, Petty TL. Complications and consequences of endotracheal intubation and tracheotomy. A prospective study of 150 critically ill adult patients. *Am J Med* 1981;70:65-76. Stauffer JL, Olson DE, Petty TL. Complications and consequences of endotracheal intubation and tracheotomy. A prospective study of 150 critically ill adult patients. *Am J Med* 1981;70:65-76.
14. Goldenberg D, Golz A, Netzer A, Joachims HZ. Tracheotomy: Changing indications and a review of 1,130 cases. *J Otolaryngol* 2002;31:211-5.
15. Mohiuddin A, Shabir A. Case report - Submental intubation in extensive maxillofacial trauma. *Anaesth Pain Intensive Care* 2010;15:182-4.
16. Meyer C, Valfrey J, Kjartansdottir T, Wilk A, Barrière P. Indication for and technical refinements of submental intubation in oral and maxillofacial surgery. *J Craniomaxillofac Surg* 2003;31:383-8.