

Descriptive analysis of Traumatic Cataract Cases with Special Reference to its Surgical Outcomes

Dr. Meghna Solanki^{1§}, Dr. Nimesh Jain² and Dr. Kishore Kumar³

^{1,2}Resident, Department of Ophthalmology, SMS Medical College, Jaipur (Rajasthan) India.

³Professor, Department of Ophthalmology, SMS Medical College, Jaipur (Rajasthan) India

Abstract— Traumatic cataract is the commonest complication causing diminution of the vision following any type of ocular injury. It causes serious visual disability in working population So this study was aimed to analyse the post traumatic cataract cases and to observed its surgical outcomes. This study was conducted on 47 post traumatic cataract cases attended at Ophthalmology department of SMS Medical college, Jaipur. Present study observed that males predominate over females in traumatic cataract with M:F ratio 2.7 and majority (59%) of cases were below 20 years of age. The most common mode of injury was wooden stick in 40.43% cases followed by stone in 23.40%. 85.5% patients had pre operative visual acuity below hand movement in affected eye. In most of the cases IOL was implanted successfully and only one case left aphakic due to inadequate zonular support. Intraoperative posterior capsular rent occurred in 1 case, and vitreous prolapse in 2 cases. Postoperative complications were striate keratopathy, AC reaction, residual cortical matter and hyphema. In this study final visual outcome in affected eye were as follows-44.68% patients -20/20 – 20/30, 38.30% patients – 20/40 - 20/60. 82.98% patients were gain satisfactory final visual outcome. 17.02% patients have visual acuity below 20/80, due to the co-morbidity.10.64% patients have posterior capsular opacification, 6.38% patients have vitreous hemorrhage and one patient have aphakia with vitreous hemorrhage. These all patients were referred for further management. This study concluded that final visual outcome in traumatic cataract patients in closed globe injuries is clearly related to extent of damage to anterior and posterior segment. PCIOL implantation is the best way of rehabilitation of traumatic cataract cases. Further with better surgical techniques and instrumentation, minimal handling of tissues during surgery and good pre-operative and post-operative control of inflammation better results can be achieved.

Key words: Traumatic cataract, Open globe injuries, Closed globe injuries, Surgical Outcomes, PCIOL Implantation

I. INTRODUCTION

Ocular trauma is a major cause of visual impairment worldwide⁷. There are approximately 1.6 million people who have become blind Worldwide, 2.3 million who have become bilaterally visually impaired and 19 million with unilateral visual loss due to eye injuries^{5,8,9}Ocular injuries are increasingly becoming a permanent, yet avoidable cause of blindness.

Damage to the crystalline lens is an important manifestation of ocular trauma, which results in the formation of traumatic cataract.

When the anterior surface of the eye is struck bluntly, there is rapid anterior – posterior shortening accompanied by equatorial expansion of the globe. This equatorial expansion can disrupt the lens capsule, zonules or both. Combination of coup, counter coup & equatorial expansion is responsible for formation of traumatic cataract^{1,2,3}.

Major risk factors for ocular injuries include age, gender, socioeconomic status and Lifestyle¹⁰. Ocular trauma is more common in males as compared to females^{8,9,10,11,12}. People from lower socioeconomic

strata are more commonly affected⁵. The setting for occurrence of trauma is most commonly the workplace, road traffic accidents, sports related injuries, at home and school.

This study was based on age and sex distribution of traumatic cataract, etiological factors, associated ocular injuries, associated complications, surgical management and final visual outcome in traumatic cataract following surgical management in blunt trauma.

II. METHODOLOGY

This descriptive analytical study was on traumatic cataract cases attended at department of Ophthalmology, SMS Medical College, Jaipur . Among these Traumatic cataract following open globe injuries, Previous h/o ocular surgery and Pre-existing ocular morbidity like chronic ocular diseases, glaucoma and optic nerve diseases were excluded from the study. Patient not willing to participate was also excluded from this study. Finally 47 cases with traumatic cataract due to blunt trauma were included in this study after taking informed consent from them.

After collecting biosocial identification data of these study subjects were interrogated to get detailed history regarding ocular trauma as follows:-

History and examination

1. Detailed history: Patient identification data (name, age, sex, and address)
 - History about mode and source of injuries.
 - Nature of trauma and associated ocular damage.
 - Duration between trauma and presentation of patients
 - Diminution of vision and associated complaints

After taking detailed history ocular examination was done of each study subject as follows:-

2. Ocular examination
 - Detailed anterior segment examination
 - Visual acuity (unaided, BCVA)
 - Intraocular pressure measurement
 - Posterior segment evaluation
 - B-scan ultrasonography
 - Keratometry, A-scan for IOL power calculation

Pre operative preparation was done and surgery was undertaken in which all the routine surgical steps for cataract extraction were followed, capsular bag IOL implantation was preferably tried in favorable conditions.

3. Post operative examination was done to find out
 - Discharge- present or not
 - Conjunctiva-congestion present or not

- Cornea- To evaluate its clarity, presence or absence of striate keratopathy and oedema, state of sutures (if applied).
- Anterior chamber- to look for any signs of inflammation, presence of lens matter, hyphema by slit lamp examination.
- Iris prolapse, iris capture,
- Pupil - to evaluate its size , shape and reaction.
- Lens - position of IOL
- Visual acuity (unaided and pin hole)
- Intraocular pressure
- Fundus examination

All patients with injuries and without an infection were treated with topical and systemic corticosteroid, antibiotics and cycloplegics. The duration of treatment depends on the degree of inflammation in the anterior and posterior segments of the operated eye.

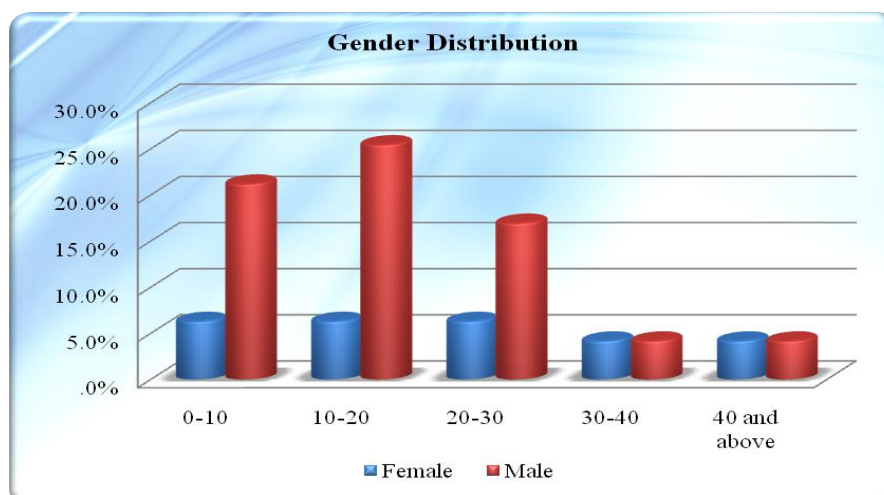
All patients were followed up at 1st day, 7th day, 14th day, 30th day and 60th day. During their follow up visits Visual acuity, intraocular pressure, anterior segment and Posterior segment examination were done.

Data thus collected were compiled in Microsoft Excel 2007 worksheet and were analysed to get inferences.

III. RESULTS

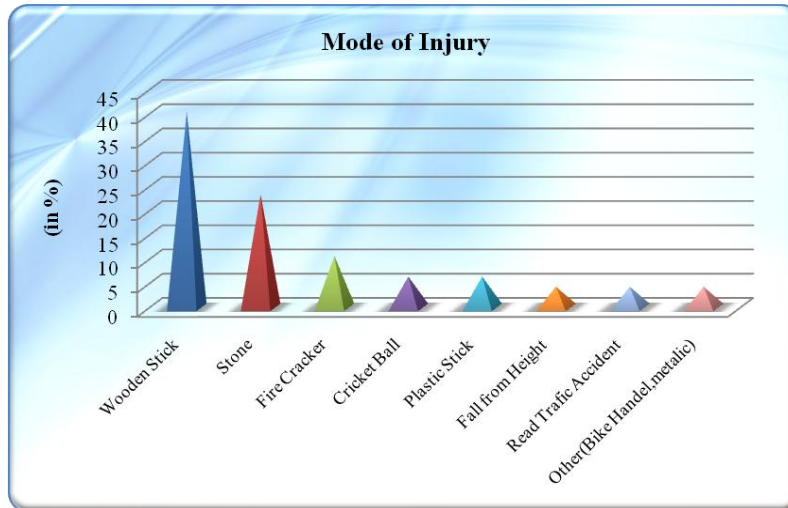
Out of these 47 cases of traumatic cataract, majority of cases were male (34 i.e. 72.3%) and remaining (13 i.e. 27.7%) were female having M:F ratio 2.7. Maximum cases were in age group of 10-20 years followed by 1-10 years. (Figure 1)

Figure 1
Age and Sex wise distribution of Study Population



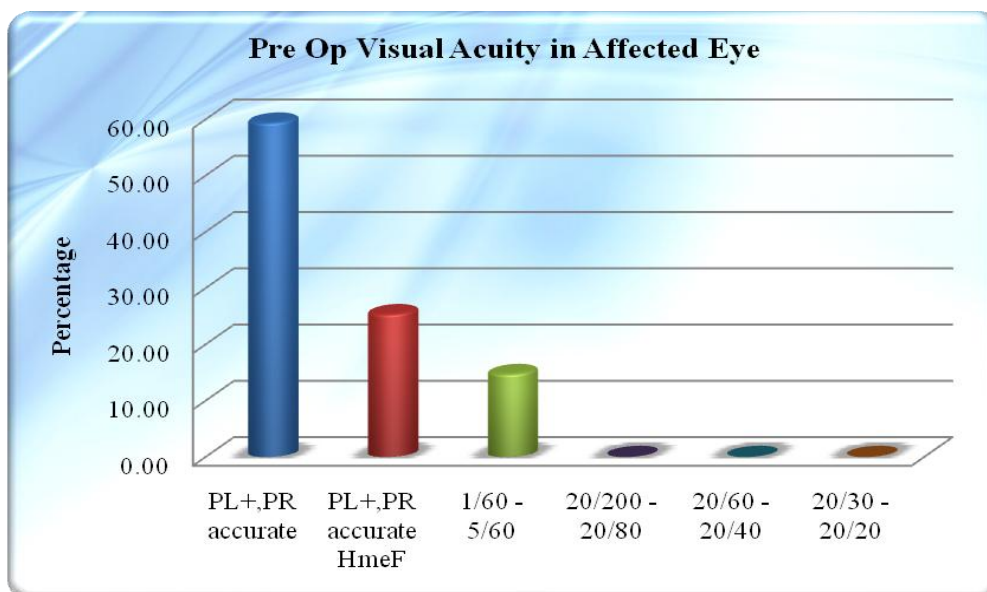
When mode of ocular injury was found out it was observed that most common mode of injury was wooden stick in 19 cases (40.43%), followed by stone 11 cases (23.40%). (Figure 2)

Figure 2
Modes of Injury wise distribution of Study Population



This study also found that pre operative visual acuity in affected eye- PL+, PR accurate in 28 cases (59.57%), PL+, PR accurate, HMcF in 12 cases (25.53%) and 7 cases have vision between 1/60 -5/60 (14.89%). (Figure 3)

Figure 3
Pre operative Visual Acuity in affected Eye



This study also observed that 74.5% cases underwent cataract aspiration with PCIOL. In 4 cases sulcus IOL were implanted due to the inadequate posterior capsular support. In 2 cases anterior vitrectomy was done due to intraoperative vitreous prolapse. (Table 1)

Table:1
Distribution of Study Population as per Type of Cataract Surgery done

S. No.	Procedure	No. of cases	Percentage
1	Cataract aspiration with PCIOL	35	74.5
2	Cataract aspiration with ant vitrectomy	1	2.1
3	Cataract aspiration with sulcus IOL	3	6.3
4	Cataract aspiration with PCIOL with iris tear repair	1	2.1
5	Phaco with PCIOL	3	6.3
6	ECCE with PCIOL	3	6.3
7	ECCE with sulcus IOL with	1	2.1
8	Total	47	100

Figure 4 is showing traumatic cataract in a patient with blunt trauma injury, while figure 5 is showing Post operative image of the same patient after traumatic cataract extraction.

Figure 4

Pre operative image showing traumatic cataract in a patient with blunt trauma injury

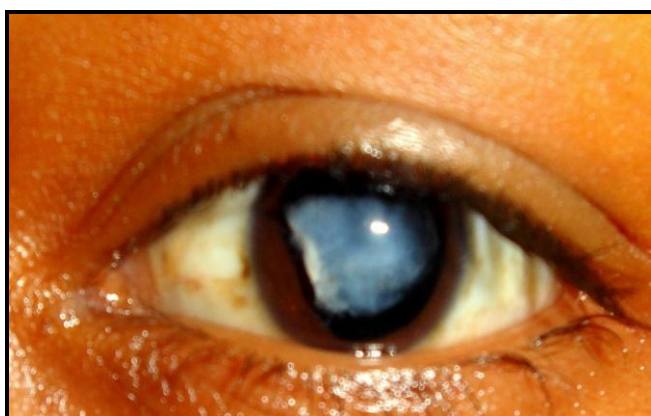
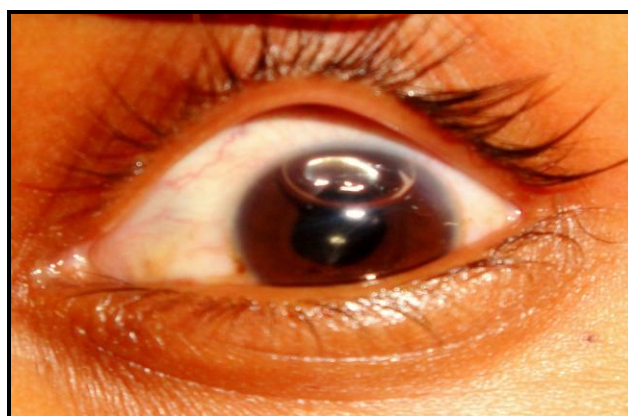
Figure 5

Post operative image of the same patient after traumatic cataract extraction



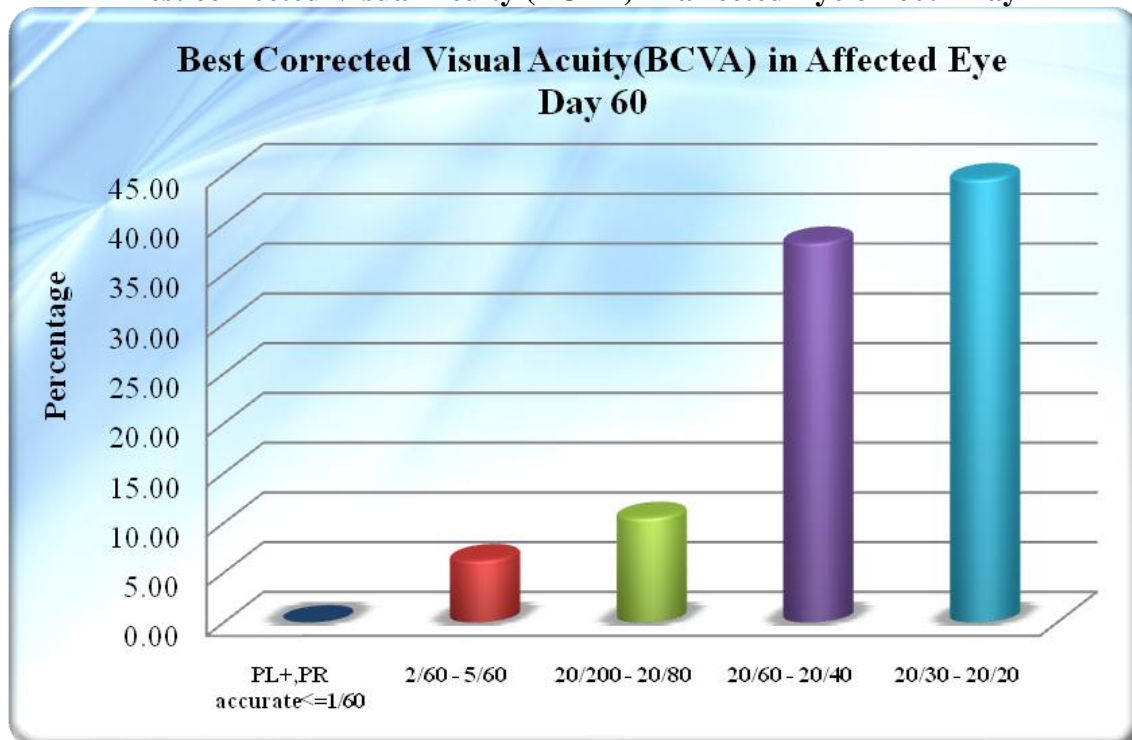
Visual acuity was 20/200-20/80 in majority of cases (63.83%), followed by 20/60-20/40. Visual acuity was found accurate ($\leq 1/60$) in affected eye in 10.64 % only on 1st day. (Table 2)

Table:2
Uncorrected Visual Acuity of affected Eye on 1st, 30th and 60th Day

S. No.	Visual Acuity	% of cases on 1st Day	% of cases on 30th Day	% of cases on 60th Day
1	PL+, PR accurate \leq 1/60	10.64	0.00	0.00
2	2/60 - 5/60	8.51	6.38	6.38
3	20/200 - 20/80	63.83	19.15	23.40
4	20/60 - 20/40	17.02	51.06	40.43
5	20/30 - 20/20	0.00	23.40	29.79
8	Total	100.00	100.00	100.00

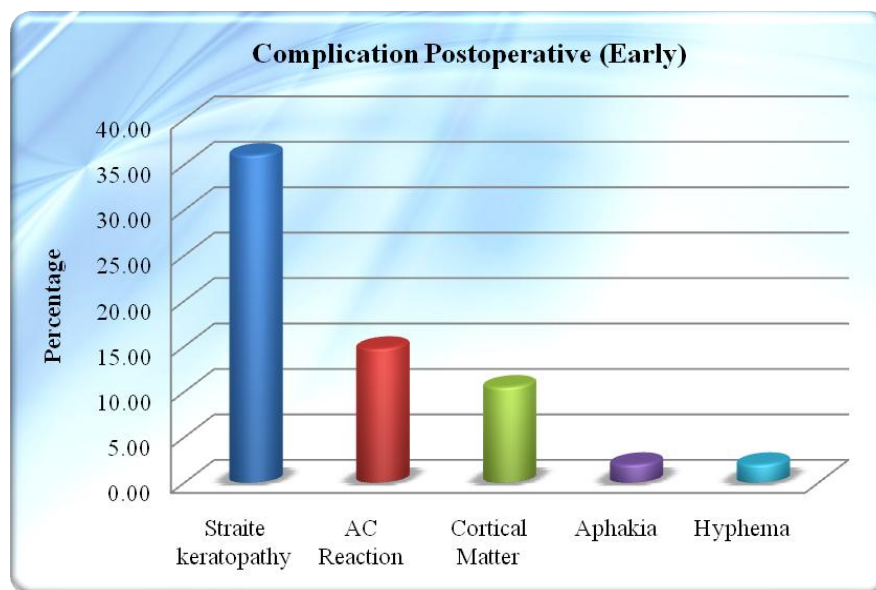
This study also observed that BCVA in affected eye at day 60: 44.68% patient have BCVA are 20/20-20/30, 38.30% patient have BCVA are 20/40-20/60, 10.64% patient have BCVA are 20/80-20/200, 6.38% patient have BCVA are below 20/200. (Figure 6)

Figure 6
Best corrected Visual Acuity (BCVA) in affected Eye on 60th Day



This study also observed that Straite Keratopathy was the most common complication observed after catatact surgery followed by AC Reaction, Cortical matter etc. (Figure 7)

Figure 7
Post-operative Complications in Study Populations



IV. DISCUSSION

This present study was conducted on 47 traumatic cataract cases attended at Upgraded Department of Ophthalmology, SMS Medical College, Jaipur.

This study observed that traumatic cataract more commonly affected the young age group. 59.6% cases were below 20 years of age. This was due to greater outdoor activities of this age group. In this study the average age was 20.57 years. Almost similar observations were made by Daljit Singh et al¹⁴ had average age of 22.9 years.

In this study male patients were 72.7% and female were 27.3% having M:F ratio 2.7. Almost similar observations were made by other authors also. A study by Mehul Shah et al (June 2011)⁶ found that 69.9% male and 30.1% were female. Ahmad B et al (1998)¹⁵ found that 76% were males and 24% were female. Singh Daljit et al (1983)¹⁴ found that 83% were male and 17% were female.

In this study most common object causing trauma was wooden stick (40.43%), followed by stone injury 23.40%, fire cracker 10.64%, cricket ball 6.38%, road traffic accident 4.26%, plastic stick and others. Mehul Shah et al (2011)⁶ study also reported that maximally (56.4%) injured were by wooden stick and 13% cases by stone.

Present study also observed posterior capsule rupture in 2.13% cases, iris prolapse and vitreous prolapse in 4.26% cases and 2.13% cases left aphakic due to the lack of Zonular support.

Postoperatively Striate Keratopathy was found in 36.17% cases, anterior chamber reaction in 14.89% cases, residual cortical matter in 10.64% cases and hyphaema noted in 2.13% cases. Similar observations were reported by V.L. Loncar (2004)¹⁶ who found posterior capsule rent in 12.4% cases. More closure to the present study observations were of Singh Daljit (1983)¹⁴ study who reported Striate Keratopathy in 29.4% cases.

The best-corrected visual acuity of operated eye was assessed at 6 weeks and it was found that final visual acuity were 20/60 or better in 82.98% cases. 10.64% cases have 20/80- 20/200 and only 6.38% cases have visual acuity below 5/60. In our study 17.02% patients did not gain satisfactory vision because of the involvement of posterior segment (vitreous hemorrhage, RD etc.)

Thus this present study concludes that Traumatic cataract can be successfully managed surgically with intraocular lens implantation with good visual outcome unless there are associated anterior and posterior segment injuries.

V. CONCLUSION

Present study concludes that males predominate over females in traumatic cataract with M:F ratio 2.7 and majority of cases were below 20 years of age. The most common mode of injury was wooden stick followed by stone. Majority of patients had pre operative visual acuity below hand movement in affected eye. In most of the cases IOL was implanted successfully and only one case left aphakic due to inadequate zonular support. It was also concluded from this study that final visual outcome in traumatic cataract patients in closed globe injuries is clearly related to extent of damage to anterior and posterior segment. PCIOL implantation is the best way of rehabilitation of traumatic cataract cases. Further with better surgical techniques and instrumentation, minimal handling of tissues during surgery and good pre-operative and post-operative control of inflammation better results can be achieved.

CONFLICT OF INTEREST

None declared till now.

REFERENCES

1. Schwab IR et al. Anterior segment trauma. In AAO Basic and clinical science course Section 8 1997:285-6.
2. Witherspoon CD, Kuhn F, Morris R, et al. Anterior and posterior segment trauma. Master Techniques in Ophthalmic Surgery. 1995;538-47
3. Tabatabali A, Kiyarudi MY, Ghassemffi, Moghni S, Monsouri M, et al. Evaluation of posterior capsule by 20 Mhz ultrasound probe in traumatic cataract
4. Andrew LAM, William E, Benson and Jhan B, Jaffers blunt trauma chapter 31
5. MacEwen CJ, Eye Injuries. Prospective Survey of 5671 cases. *Vr J Ophthalmol* 1989; 73(11):888-94
6. Mehul Shah, Sherya shah et al. Visual recovery after managing traumatic cataract (IJO 2011).
7. Albert, Jakobiec. The principal and practices of ophthalmology ,third edition 2008:4:5069
8. Asminew T, Gelaw Y, Alemseged F. A 2 year review of ocular trauma in Jimma university specialized hospital. *Ethiopia J Health Sci* 2009; 19(2):67-74
9. Vats S, Murthy GV, Chandra M, Gupta SK, Vashist P, Gogoi M. Epidemiological study of ocular trauma in an urban slum population in Delhi, India. *Indian J Ophthalmol* 2008; 56(4):313-316
10. Negrel AD. Magnitude of eye injuries worldwide. *Community Eye Health J* 1997; 10(24): 49-53
11. Kararam K, Antunica AG, Rogosiae V, Lakoskrelj V et al. Epidemiology of adult eye injuries in split-Dalmatian county. *Ophthalmology* 2004; 45(3): 304-309
12. Addisu Pattern of ocular trauma seen in Garbet Hospital, Butajira, Central Ethiopia. *Ethiop J Health Dev* 2011; 25(2):150-155
13. Lane SS, Koppeitz LA, Lindquist TD et al. Treatment of Phacolytic glaucoma with ECCE, *Ophthalmology* 1998-99 749-53
14. SinghDaljit et al. The Role of intraocular lens in traumatic cataract *IJO* 1983 may :31;294-297
15. ShoabAhmed B et al. Traumatic cataract in newer perspective *Jr of TNOA* 1998 38 (8) 31-33
16. Valentina L Loncar et al. Surgical treatment, Clinical Outcome of Traumatic Cataract. *Croatian Medical Jr* 2004 45(3) 310-313