

Peripheral Ossifying Fibroma with Superficial Bone Erosion: A Case Report

Dr. Anuja Chandra¹, Dr. Hoti Lal Gupta², Dr. Pradeep Kumar³, Dr. Shradha Sethi⁴, Dr. Probal Soud⁵ and Dr. Neha Yadav⁶

^{1,5,6}Post-graduate Student, Department of Periodontology and Oral Implantology, Rajasthan Dental College, Jaipur

²Professor and Head, Department of Periodontology and Oral Implantology, Rajasthan Dental College, Jaipur

³Reader, Department of Periodontology and Oral Implantology, Rajasthan Dental College, Jaipur

⁴Senior Lecturer, Department of Periodontology and Oral Implantology, Rajasthan Dental College, Jaipur

Abstract—This study was aimed to present a case report of a case of peripheral ossifying fibroma which is a rare case. This case was a 30 years non smoker male with the chief complaint of growth of gum tissue, moderately large in the mandibular posterior region. On intraoral examination, a pedunculated growth of 17 x 12 x 6 mm on marginal and attached gingiva with respect to tooth number 47 considerably hard in consistency and movable was seen. The lesion was erythematous having a smooth non ulcerated surface. It was asymptomatic with no sign of pain. Intra oral periapical radiograph was taken which revealed slight erosion of crest of bone which was later confirmed during surgical excision. The possible reason of crestal bone erosion may be constant pressure of the growth. Differential diagnosis of irritation fibroma, pyogenic granuloma and peripheral giant cell granuloma was considered. However, clinical appearance and consistency was of a hard fibrous growth, which therefore led to a provisional diagnosis of peripheral ossifying fibroma or peripheral odontogenic fibroma.

Keywords— *Peripheral calcifying/Cementifying/Ossifying fibroma, Bone Erosion, Gingival overgrowth*

I. INTRODUCTION

Peripheral ossifying fibroma which is characterised by high degree of cellularity usually exhibiting bone formation, although occasionally cementum like material or rarely dystrophic calcification may be found instead¹

There are numerous histologically different types of focal overgrowth which may occur on the gingiva, such as peripheral giant cell granuloma, giant cell fibroma, pyogenic granuloma, simple fibroma (which may be simply a healed pyogenic granuloma in many cases) and the present lesion which has been known by names like peripheral odontogenic fibroma, peripheral cementifying fibroma, calcifying or ossifying fibroid epulis and peripheral fibroma with calcification in the past. The lesions have a more female predilection (female: male – 4.3:1) with reported recurrence as high as 20%, and a nearly equal maxilla to mandible ratio has been recorded².

II. METHODOLOGY

An unusual case with the chief complaint of growth of gum tissue, moderately large in the mandibular posterior region was reported to Department of Periodontology and Oral Implantology, in a hospital attached to Rajasthan Dental College, Jaipur (Rajasthan) India. After taking consent from the the case, variables regarding detailed history, examination and investigations were recorded. Tissue was excised and sent for histo-pathological examination in pathology department. Pathological finding confirmed the case as Peripheral ossifying fibroma with bony erosion. Case was treated and followed for 6 months. Findings regarding prognosis was also recorded. Pictures of case at different time of study were also taken.

III. CASE REPORT

A case with the chief complaint of growth of gum tissue ,moderately large in the mandibular posterior region was reported to Department of Periodontology and Oral Implantology, in a hospital attached to Rajasthan Dental College, Jaipur (Rajasthan) India. He was a 30 years non smoker male from middle socio economic class. This present lesion was present for approximately three years. Other medical history was irrelevant and insignificant with this lesion.

On intraoral examination, a pedunculated growth of 17 x 12 x 6 mm on marginal and attached gingiva with respect to tooth number 47 considerably hard in consistency and movable was seen. The lesion was erythematous having a smooth non ulcerated surface. It was asymptomatic with no sign of pain. (Figure 1)

Intra oral periapical radiograph was taken which revealed slight erosion of crest of bone which was later confirmed during surgical excision. The possible reason of crestal bone erosion may be constant pressure of the growth. (Figure 2)

Differential diagnosis of irritation fibroma, pyogenic granuloma and peripheral giant cell granuloma was considered. However, clinical appearance and consistency was of a hard fibrous growth, which therefore led to a provisional diagnosis of peripheral ossifying fibroma or peripheral odontogenic fibroma.

Figure 1

Soft tissue growth in respect to tooth number 47

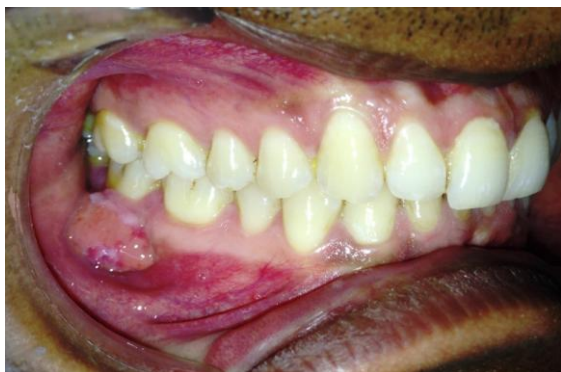
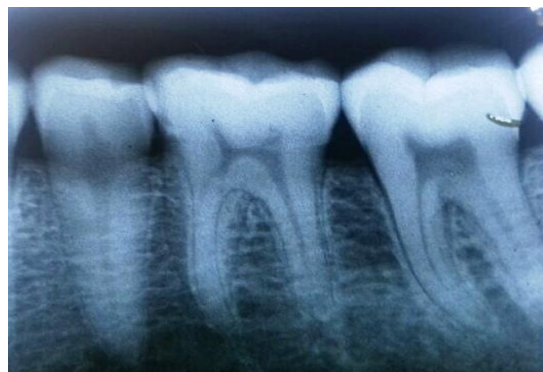
Figure 2

IOPA showing soft tissue shadow



PROCEDURE:

Phase I periodontal therapy was carried out, excision and microscopic examination were planned and patient's consent for the same was taken.

Under local anesthesia, the whole growth was excised using electrocautery and underlying surface was thoroughly curetted upto deepest possible tissue followed by crestal osteoplasty. After controlled bleeding, patient was discharged with the prescription of pain killer and chlorhexidine mouth wash. (Figure 3)

The excised tissue was submitted to Department of Oral Pathology for histopathological examination.

The H and E stained soft tissue section showed fibrous connective tissue comprising of bundle of collagen fibers in cellular stroma. It includes fibroblasts, calcification, chronic inflammatory cells comprising mostly of lymphocytes and blood vessels. (Figure 4)

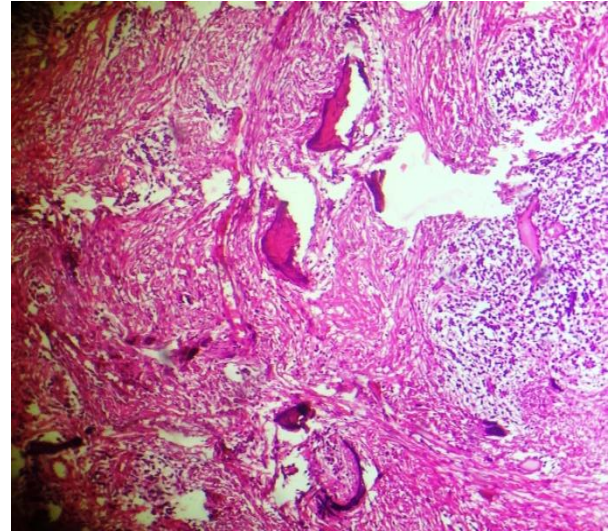
Figure 3

After excision by Electrocautery

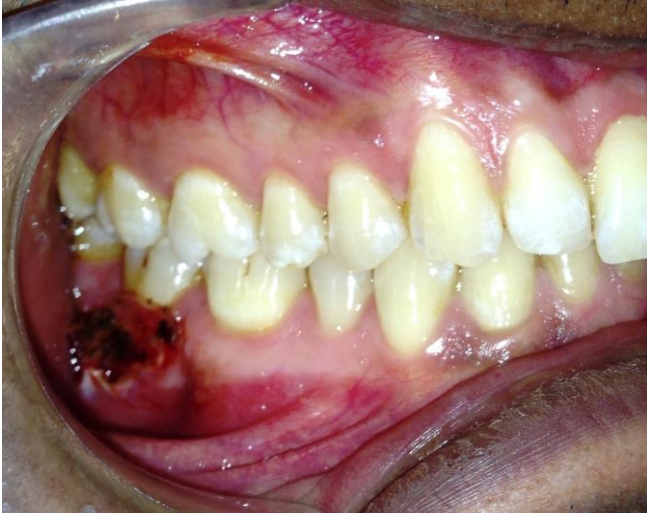

Figure 4

Histopathological section of excised tissue (showing fibroblastic stromal calcifications)



DIAGNOSIS:

The clinical assessment and histopathological diagnosis confirmed the lesion as peripheral ossifying fibroma.

FOLLOW UP:

Since alveolar bone was eroded by the lesion, follow up visits were arranged post one week, 1, 3 and 6 months. The surgical site appeared to be healing well and there was no evidence of recurrence of the lesion. (Figure 5 & 6)

Figure 5

Normal healing of lesion post one week

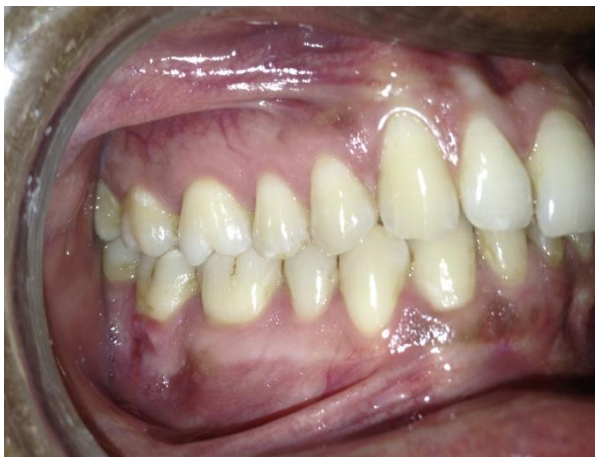
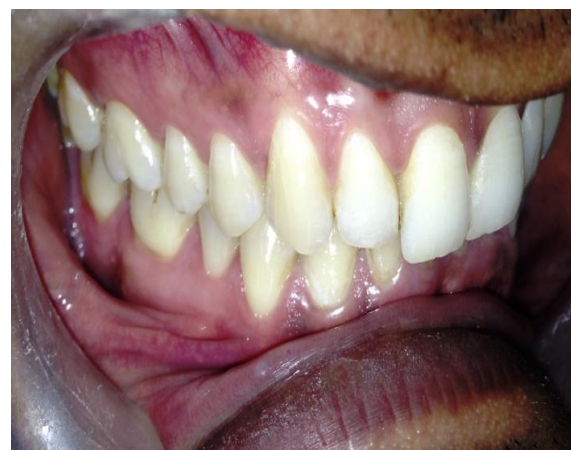
Figure 6

Follow up after six months



IV. DISCUSSION

The etiopathogenesis of peripheral ossifying fibroma is uncertain. The term POF was coined by Eversole LR and Rovin S in 1972³. It occurs extensively on gingiva. It is relatively common growth of gingiva and is considered to be reactive in nature rather than neoplastic⁴. Cundiff reported that the lesion is prevalent between ages of 5 and 25 years with peak incidence at 13 years of age with definite female predilection⁵. The site of occurrence is usually anterior to molars in both maxilla and mandible equally and in more than 50% of the cases in incisors and cuspid regions.

It may be present as a pedunculated nodule or it may have a broad attachment base. These lesions can be red to pink with areas of ulceration and their surfaces may be smooth or irregular. Cases of tooth migration and bone destruction have been reported but they are not very common^{6,7,8,9}.

POF's are believed to arise from gingival fibers of the periodontal ligament as hyperplastic growth of tissue that is unique to the gingival mucosa¹⁰. Histopathologically, the lesion shows stratified squamous epithelium covering an exceedingly cellular mass of connective tissue made up of fibrillar stroma, fibroblasts, fibrocytes and areas of mineralization with multinucleated giant cells near them in some cases¹¹.

Treatment consists of conservative surgical excision. However the rate of recurrence is reported to be 14%⁶, 9%⁸, 16%¹² and 20%³. Thus, a regular follow up is a must. An incomplete surgical removal of the lesion can also be possible cause of recurrence.

V. CONCLUSION

To conclude, peripheral cemento ossifying fibroma is a non neoplastic enlargement of the gingiva that is classified as a reactive hyperplastic inflammatory lesion. It resembles peripheral giant cell granuloma, pyogenic granuloma and irritation fibroma, hence thorough knowledge and histopathological examination is important to draw a conclusion.

CONFLICT OF INTEREST

None declared till now.

REFERENCES

1. Shafer's textbook of Oral Pathology 6th edition
2. Bodner L, Dayan D. Growth potential of peripheral ossifying fibroma. J Clin Periodontol. 1987;14:551-4.
3. Eversole LR, Rovin S Reactive lesions of the gingiva J Oral Pathol 1972 1(1): 30-38
4. Fausto KA. Robbins and Cotran pathologic basis of disease. 7th ed. Philadelphia: WB Saunders; 2008. pp. 775-6.
5. Cundiff EJ. Peripheral ossifying fibroma: A review of 365 cases. USA: MSD Thesis Indiana University; 1972.
6. Kenney JN, Kaugars GE, Abbey LM. Comparison between the peripheral ossifying fibroma and peripheral odontogenic fibroma. J Oral Maxillofac Surg. 1989;47:378-82.

7. Skinner RL, Davenport WD, Jr, Weir JC, Carr RF. A survey of biopsied oral lesions in paediatric dental patients. *Pediatr Dent*. 1986;8:163-7.
8. Cuisia ZE, Brannon RB. Peripheral ossifying fibroma v A clinical evaluation of 134 paediatric cases. *Pediatr Dent*. 2001;23:245-8.
9. Das S, Das AK. A review of paediatric oral biopsies from a surgical pathology service in a dental school. *Pediatr Dent*. 1993;15:208-11
10. Miller CS, Henry RG, Damm DD, Proliferative mass found in the gingiva, *J Am Dent Association* 1990; 121(4),559-560
11. Neville BW, Damm DD, Allen CM, Bouquet JE. *Oral and Maxillofacial Pathology*. 2nd ed. New Delhi: Elsevier; 2005. pp. 563-4.
12. Buchner A, Hansen LS. The histomorphologic spectrum of peripheral ossifying fibroma. *Oral Surg Oral Med Oral Pathol*. 1987 Apr; 63(4):452-61.