

# Acute Pyogenic Meningitis: An Autopsy Case Report

Kinako Sam Ewune<sup>1\*</sup>, Izein Narugayam Claudius<sup>2</sup>, Wala kelachi Thankgod<sup>3</sup>,  
Solomon Obioha<sup>4</sup>

<sup>1</sup>Department of Anatomical Pathology, Rivers State University, Nkpolu-Oroworukwo, P.M.B 5080, Port Harcourt, Rivers State, Nigeria

<sup>2</sup>Department of Anatomical Pathology, Federal Medical Centre, P.M.B 502, Yenagoa, Bayelsa State, Nigeria

<sup>3</sup>Department of Chemical Pathology, Rivers State University, Nkpolu-Oroworukwo, P.M.B 5080, Port Harcourt, Rivers State, Nigeria

<sup>4</sup>Department of Anatomical Pathology, Rivers State University, Nkpolu-Oroworukwo, P.M.B 5080, Port Harcourt, Rivers State, Nigeria

\*Corresponding Author

Received:- 06 January 2023 | Revised:- 13 January 2023 | Accepted: 19 January 2023 | Published: 31-01-2023

Copyright © 2021 International Multispecialty Journal of Health

This is an Open-Access article distributed under the terms of the Creative Commons Attribution Non-Commercial License (<https://creativecommons.org/licenses/by-nc/4.0>) which permits unrestricted Non-commercial use, distribution, and reproduction in any medium, provided the original work is properly cited.

**Abstract**— Acute pyogenic meningitis may be complicated by tonsillar herniation and this makes the clinical management of the patient very arduous and may lead to death. We report a case of a 13-year-old female admitted to the children emergency unit due to meningitis secondary to lobar pneumonia. The autopsy showed central cyanosis, lobar pneumonia, cerebral oedema, exudate around the brain, cerebral oedema and tonsillar herniation. Brain smear revealed numerous gram-positive cocci in chains. The cause of death was tonsillar herniation secondary to acute pyogenic meningitis.

**Keywords**— Autopsy, lobar pneumonia, acute pyogenic meningitis, cerebral oedema, tonsillar herniation.

## I. CASE REPORT

A 13-year-old-female who was admitted to the Emergency ward with complaints of non-paroxysmal cough, difficulty in breathing and fever of a week duration. She also complained of headache of two days duration and loss of consciousness of a day duration. There is no history of trauma.

She was acutely ill-looking, anicteric, moderately pale and with central cyanosis. Her neck was stiff and her respiratory rate was 14cpm (20-25 breaths/minute), pulse rate 66bpm (75-110bpm), temperature 39 degrees celcius (35.9-37.6° Celcius) and blood pressure was 140/100mmHg. She was unconscious and with a glasgow coma scale of 4/15 (eye opening=1, best motor response=2, best verbal response=1). She was in marked respiratory distress. There was reduced air entry over the lung fields and few basal crepitation which were more prominent over the left lungs. Physical examination of other systems was normal.

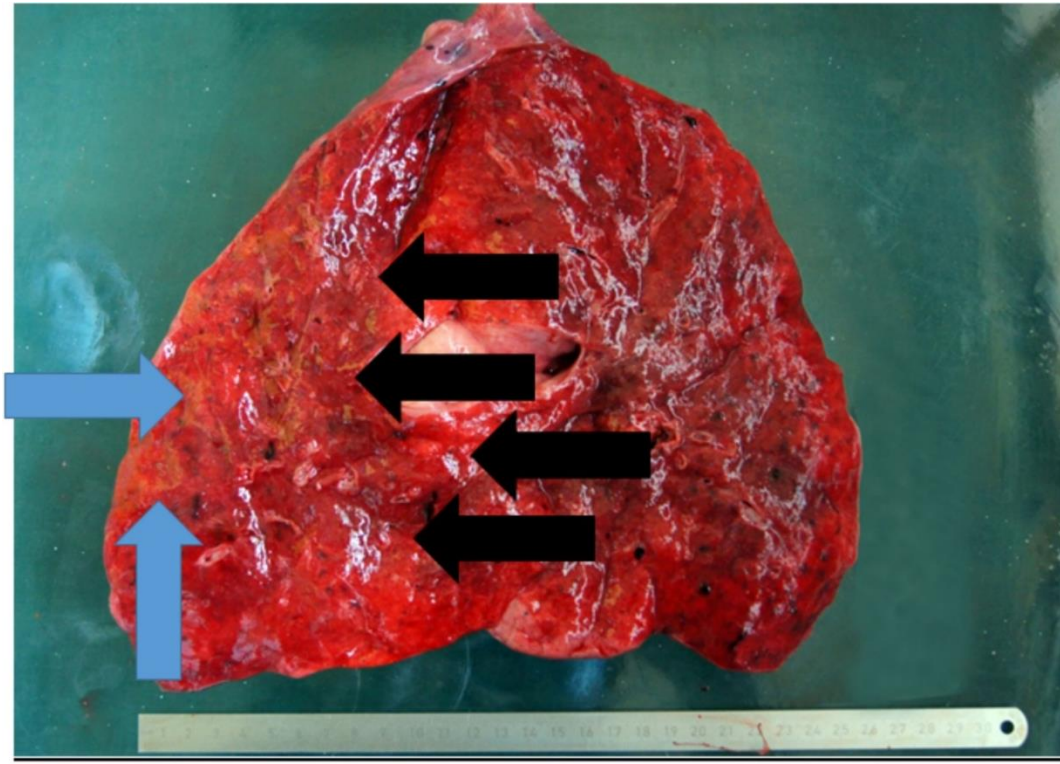
The laboratory work up revealed a hemoglobin of 9.0g/dl (Reference Value {RV}: 11.5-16.5g/dl). Her random blood sugar was 8.0mmol/l (RV: below 11.1mmol/l). Her thick and thin blood film for malaria parasite was negative.

She received start doses of intravenous mannitol, ceftriazone, paracetamol and artesunate. She was intubated and placed on mechanical ventilation. She also received intranasal oxygen. Her clinical condition kept on deteriorating and with a glasgow coma scale of 3/15. Her respiration was also deteriorating and she was gasping for air. She was noticed to have stopped breathing about 90 minutes after admission and despite attempts at resuscitation. She was certified dead and her body was moved to the morgue for autopsy. She was managed as a case of meningitis on background lobar pneumonia.

## II. AUTOPSY FINDINGS

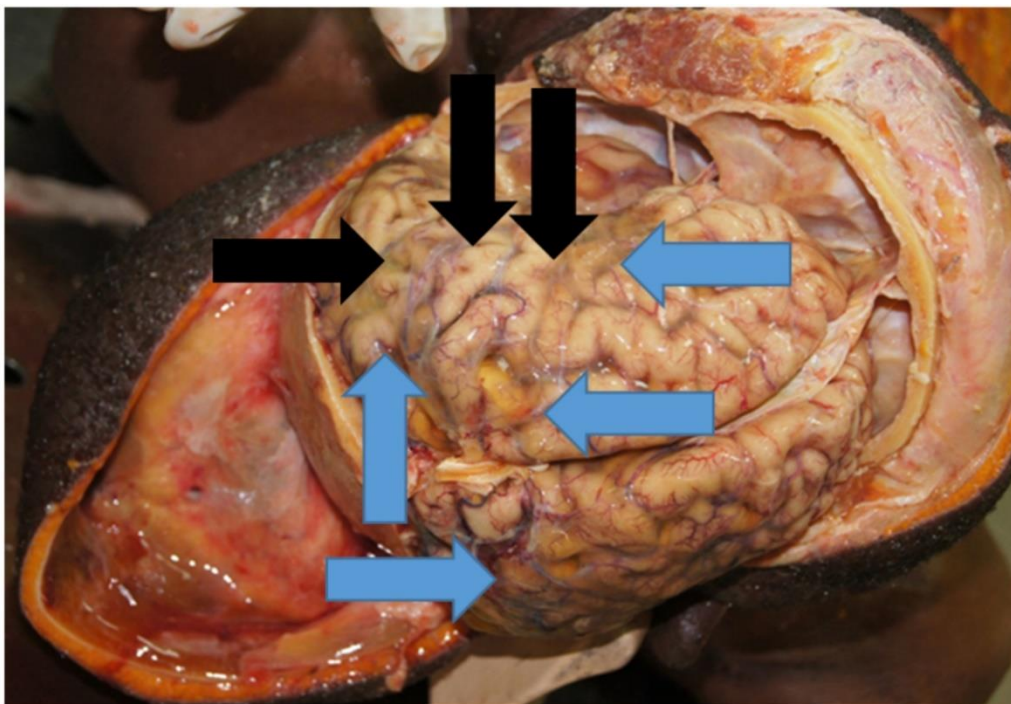
The corpse weighed 28kg and measured 140cm in length, the body mass index is 14.3kg/m. Her mid-upper arm circumference is 12.5cm. She is anicteric, mildly pale and with central cyanosis. The external ear appear normal. There is no lymphadenopathy and no oedema. Her external genital appear normal and the internal examination revealed no pneumothorax and all organs are in their normal anatomical positions. The pleural, pericardial and peritoneal cavities appear normal. The laryngeal cartilage, hyoid bone and soft tissues of the neck are normal. The mucosa of the oropharynx, nasopharynx, laryngopharynx, trachea and

bronchi are normal. The right lungs weigh 180gms (RV: 170-180gms) the cut surface appear normal. The left lungs weigh 220gms (RV: 160 – 170gms). The cut surface of the lower lobe is reddish-brown, firm, friable and appears liver- like consistency (red hepatization). There is also scattered fibrinous exudate on the cut surface (figure 1).



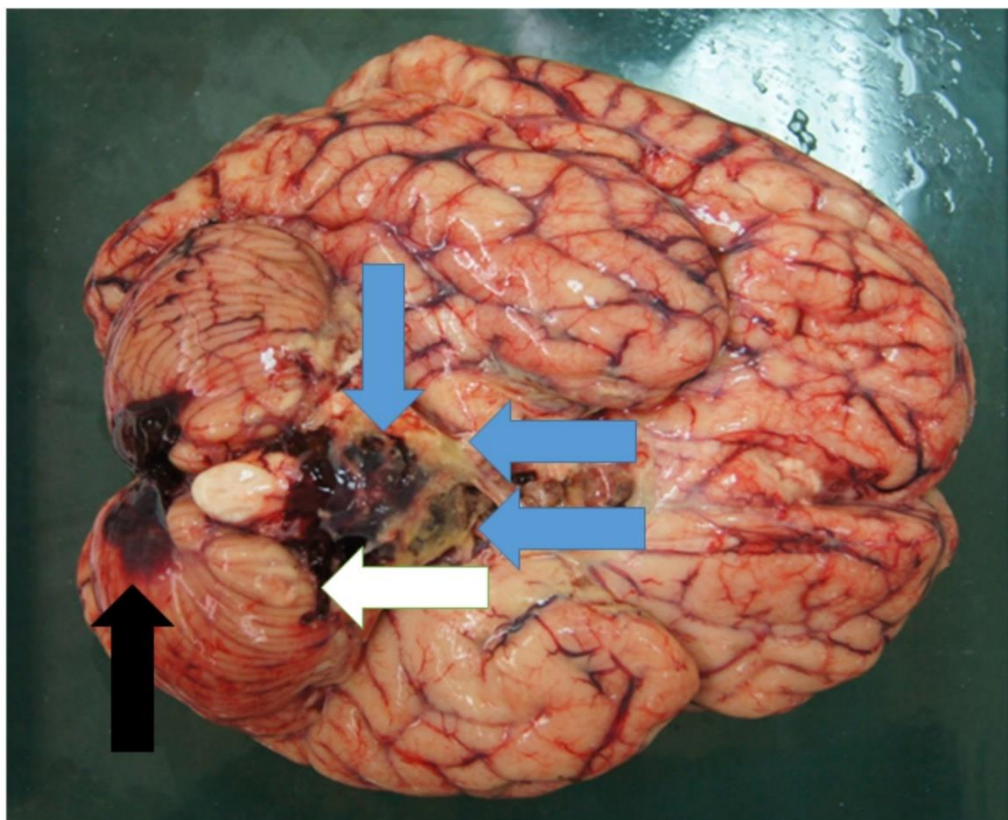
**FIGURE 1: Showing the cut surface of the right lungs; (a) the blue arrows show areas with fibrinous exudate. (b) the black arrows show areas with red hepatization.**

The scalp, skull and dura are normal. The brain weighs 1400gms (RV: 1260 – 1300gms). The leptomeninges were opaque in arrears and is due to the presence of a whitish-yellow exudate (figure 2).



**FIGURE 2: (a) blue arrow; Showing opaque meninges due to the presence of a whitish–yellow exudate. (b) black arrow; showing widened of the gyri and some of the gyri appear flat.**

There are also engorged vessels in the leptomeninges. There are areas showing narrowing of the cerebral sulci and widened of the gyri. Some of the gyri appear flat (see figure 2) and this is due to the persistent compression of that part of the cerebrum on the skull. The serial coronal sections of the cerebrum revealed seepage of fluid from the cut surface and easily stripped leptomeninges from the surface of the cerebrum. The gray and white matter show no other lesions or hemorrhage. There are whitish-yellow exudate and blood clots around the brain stem (figure 3).



**FIGURE 3: His brain. (a) blue arrows; showing whitish-yellow exudate and blood clots around the brain stem. (b) black arrow; showing blood clots around the posterior aspect of the cerebellum. (c) white arrow; showing a groove seen on cerebellar tonsils.**

The serial cut sections through the brain stem show no lesions on gross. There are blood clots around the posterior aspect of the cerebellum. There is also a groove around the cerebellar tonsils (this is suggesting cerebellar tonsillar herniation). The serial cut sections through the cerebellum show normal gray and white matter differentiation. The vessels that form the arterial circle of Willis and the internal carotid arteries appear normal. The spinal cord has been not examined.

The right and the left middle ear and inner ear show no lesions on gross. The paranasal sinuses appear normal. The peripheral nerves were exposed during routine dissections and appear normal. Other organs appear normal.

The histology of the left lungs shows massive confluent exudation with neutrophils and red cells filling the alveolar spaces. The alveolar wall shows congested blood vessels. The histology of right lungs shows normal alveoli spaces and wall. These features are consistent with lobar pneumonia of the left lung. The cerebrum shows neuronal cell body within an eosinophilic fibrillary background. There is widening and aggregates of neutrophils in the Virchow-robin's perivascular space. There are abundant neutrophils and exudates within the meninges. The histology of the brainstem shows neutrophils and exudates within the overlying meninges. The histology of the midbrain and the pons show few congested vessels. The histology of the medulla oblongata shows numerous congested vessels, areas of hemorrhage and necrosis. The histology of the cerebellum show neutrophils within the overlying meninges. There are congested vessels. These features are consistent with cerebral oedema, meningitis and suggesting tonsillar herniation. The histology of other organs is essentially normal. The brain smear stained with gram stain show numerous gram positive cocci in chains. The brain smear stained with haematoxylin and eosin stain is hypercellular and show aggregates of neutrophils within a background of amorphous eosinophilic materials. These features are consistent with purulent exudate. The findings from the autopsy points towards tonsillar herniation due to acute pyogenic meningitis as the cause of death.



### III. DISCUSSION

The case herein describes a fatal outcome of acute pyogenic meningitis in a thirteen-year-old female. Acute pyogenic meningitis remain a devastating disease<sup>1</sup> and it is still responsible for substantial morbidity and mortality in both developing and developed countries.<sup>2,3</sup> The mortality rate is approximately 5%, and the long-term morbidity, mainly consisting of persistent neurological sequelae, is fifteen percent.<sup>3</sup>

Her clinical history, revealing cough and difficulty in breathing correlates with the post mortem finding revealing consolidation in the left lower lobe. Also, the history of convulsion is consistent with the post mortem findings revealing meningitis, cerebral oedema and tonsillar herniation.

The presence of bacteria within the meninges can induce inflammation and subsequently lead to increased intravascular permeability and disruption in the blood brain barrier. This will eventually lead to an increase in the brain volume (cerebral oedema) as was seen in the index case. Also, persistent an increase in the volume of the brain beyond the limit permitted may cause compression of veins, reduce perfusion of the brain and displacement of cerebrospinal fluid which will eventually lead to an increase in the intracranial pressure. If this is not properly managed as was seen in the index case. This raise in pressure within the fixed capacity of the skull may commute into displacement of some parts of the brain through the openings within the skull (herniation) as was seen in this case. The index case illustrates tonsillar herniation which is a life-threatening event because there is compression of brainstem and also compromise of the vital respiratory and cardiac centers in the medulla oblongata.

### IV. CONCLUSION

Acute pyogenic meningitis may lead to death, especially in the presence of a fatal complication like tonsillar herniation which obviously played key role in the demise of the patient. The autopsy was essential to clarify the cause of death in this young patient.

### REFERENCES

- [1] Griffiths, M. J., McGill, F., & Solomon, T. (2018). Management of acute meningitis. *Clinical medicine (London, England)*, 18(2), 164–169.
- [2] Molyneux E, Riordan FA, Walsh A: Acute bacterial meningitis in children presenting to the Royal Liverpool Children's Hospital, Liverpool, UK and the Queen Elizabeth Central Hospital in Blantyre, Malawi: a world of difference. *Ann Trop Paediatr*. 2006, 26: 29-37. 10.1179/146532806X90583.
- [3] Saez-Llorens X, McCracken GH: Bacterial meningitis in children. *Lancet*. 2003, 361: 2139-2148. 10.1016/S0140-6736(03)13693-8.