

# Glycolic Acid Peels Versus Salicylic Acid Peels in Atrophic Acne Scars : A Randomized Comparative Study

Dr. Saroj Purohit<sup>1§</sup>, Dr. Ram Singh Meena<sup>2</sup>, Dr. Babita Bargujar<sup>3</sup> and Dr. Anil Kumar Jain<sup>4</sup>

<sup>1,2</sup>Professor, Department of Dermatology, Venereology and Leprology, SMS Medical College, Jaipur (Rajasthan) India

Email of Corresponding Author: [sarojpurohit67@gmail.com](mailto:sarojpurohit67@gmail.com)

<sup>3</sup>Junior Resident, Department of Dermatology, SMS Medical College, Jaipur (Rajasthan) India

<sup>4</sup>Consultant Dermatologist, Jaipur (Rajasthan) India

**Abstract**—Scarring is a well recognized sequel of acne. Because of the prevalence of acne scarring and strong negative emotions it engendering affected patients, several approaches have been developed for its treatment with varying success rates. Glycolic acid 50% peels and Salicylic acid 30% Peels are classified as superficial peel and are consider safe in Indian patients. While chemical peels are widely being used in India for various indications. There is a paucity of published studies on the efficacy of chemical peel specifically for acne scars in Indian patients.

*Purpose of this study was to evaluate and compare the effectively of these two agents in the treatment of acne scars. Eighty cooperative patients[≥18 years age]with predominantly moderately atrophic acne scarring were randomly divided into 2groups of 40each. Patients of group A received Glycolic acid peels and patients in group B, Salicylic acid was used at 3weeks interval for four sessions. Objective evaluations of treatment response. Subjective assessments of treatment response were also done separately by the researcher, an independent observer and the patients separately.*

*Both of agents led to significant reduction in the total acne scar score[p< 0.05]but no significant difference was noted between the two peels. Side effects were lesser with Salicylic acid peel.*

*Hence conclusion was drawn that both 50% Glycolic acid and 30% Salicylic acid peels are safe in Indian skin and equally effective in the treatment of mild to moderate acne scarring.*

**Keywords**— Acne Scare, Acne Peels, Glycolic acid peel, Salicylic acid peel

## I. INTRODUCTION

Acne vulgaris is ubiquitous with varying degrees of severity and affects approximately 85% of individual at some time between the age of 12 and 24years. Inflammatory acne lesions can results in permanent scars, severity of which may depend on delays in treating acne patients. Prevalence and severity of acne scarring in general population were studied very few authors<sup>1-3</sup> they reported that nearly 1% of people had acne scars, although only one in 7 of these cases were consider to having “disfiguring scars”.<sup>1-3</sup> Severe scarring caused by acne is associated with substantial physical and psychological distress particularly in adolescents.

Goodman and Baron<sup>4</sup> proposed a simple and universally applicable acne scar classification system to assess the of severity acne scars on objective lines. On identifying and grading the scars, an appropriate

treatment protocol can be made. There are various modalities of ablative and non ablative treatment for acne scars.

Chemical peeling has been used for acne for many years. In addition to its epidermal resurfacing properties, it leads to remodeling of collagen and elastin fibers and deposition of glycosaminoglycans, thereby decreasing scars. They are classified by depth of action into superficial, medium and deep peels.

Glycolic acid 50% peels and Salicylic acid 30% peels are superficial peel and are considered safe in Indian patients. While chemical peeling is widely being performed on Indian skin for various other indications. There is a paucity of published studies on the safety and efficacy of chemical peels specifically for acne scars in Indian patients. So, the purpose of this study is to evaluate and compare the affectivity of these two agents in the treatment of acne scars.

## II. METHODOLOGY

A randomized comparative study was conducted on Acne patients in department of dermatology of SMS Medical college, Jaipur Rajasthan India. This study was approved by Institution Research Review Board and Ethical Committee.

For the study purpose 80 cooperative patients aged  $\geq 18$  years with predominantly moderately atrophic acne scarring were taken after excluding patients with a history of hypertrophic scarring, keloids, photosensitivity, active or recurrent herpes, unrealistic expectations. Finally as per inclusion and exclusion criteria 80 patients were included in this study. After taking gave informed consent, they were randomized by computer generated random number table. These 80 patients were divided randomly in two group, group 'A' who was given Glycolic acid 50% and group 'B' who was given Salicylic acid 30%. General information with detailed history was taken and acne scoring were carried out. In Group 'A' patients Glycolic acid 50% was used for chemical peeling whereas in Group 'B' Salicylic acid 30% was used. And finally out of 40 patients from each group 36 from Group 'A' and 37 from Group B completed the study.

**Procedure:** A small circular area in the post auricular region was subjected to test peeling, one week prior to carrying out full face peeling to detect any adverse reaction. Patients were asked to wash their face with soap and water. Hairs were pulled back with a hair band. Then these patients were asked to lie down with head elevated to 45degree with eye closed. Using 2'' $\times$  2'' gauze pieces, the skin was cleaned with alcohol and then degreased with acetone. Sensitive areas like the inner canthus of the eyes and nasolabial folds were protected with petrolatum. The peeling agent was then applied with a brush, over the face in a predetermined clockwise manner starting over the forehead, right cheek, chin, and left cheek, taking about 30 seconds to accomplish the procedure. Approximately 1ml solution per session was used. Feathering strokes were applied at the edges to blend with surrounding skin and prevent demarcation lines.

For Glycolic acid peels (Group A), the peel was neutralized after the predetermined duration of times[usually three minutes]. However, if erythema or epidermolysis occurred, seen as grayish white

appearance of the epidermis, the peel was neutralized immediately irrespective of the duration. Neutralization was done with 10% sodium bicarbonate solution and then, washed off with water. When Salicylic acid peel (Group B) was applied, most patients developed a uniform white crystalline precipitate, "pseudofrost" in the peeled areas. It is then wash washed after 3-5 minutes, after the burning subsides.

Patients were asked to wash with cold water until the burning subsides. They were then asked to dry their face by pat not by rub. Following the peel, patients were advised to apply sunscreens and were sent home with instructions to apply a moisturizing cream if the facial skin felt too dry and to avoid or minimize sun exposure.

In both groups, total 4 peeling sessions were carried out at 3 weeks interval on each patient. Evaluation and scoring was done before each peel and 4 week after the last peel. Acne scar score was calculated at each visit and recorded in proforma.

Objective assessment was done by researcher by comparing the changes in the Quantitative global acne scarring score at each visit. Quantitative global acne scarring score was done as per "Goodman and Baron" which is based on type of scar and number of scars. his system assigns fewer points to macular and mild atrophic scars than to moderate and severe atrophic scars.<sup>4</sup> (Table 1)

**Table 1**  
**Quantitative global acne scarring scoring (Atrophic scars)**

Type of Grade		Number of Lesions (1-10)	Number of Lesions (10-20)	Number of Lesions (>20)
(A)	<b>Milder Scarring</b> (1 Point each)			
	-Macular Erythematous or Pigmented -Mildly atrophic dish like	1 Point	2 Point	3 Point
(B)	<b>Moderate Scarring</b> (2 point each)			
	-Moderately atrophic dish like -Punched out with shallow base small scar(<5mm) -shallow but broad atrophic areas	2 Point	4 Point	6 Point
(C)	<b>Severe scarring</b> (3 points each)			
	-Punched out with deep but normal base, small scars(<5mm) -Punched out with deep abnormal bases, small scars(<5mm) -Linear or troughed dermal scarring -Deep, broad atrophic areas	3 Point	6 Point	9 Point

Subjective assessment was of response also made by patients (self), researcher and by an independent observer on a 5 point visual analogue scale: either excellent (>60%) or good (31to 60%) or fair (≤30%)

or no change or worse. Subjective assessment was done by observer and researcher by comparing the clinical photograph, taken at baseline, with the actual clinical evaluation on present visit before doing next peel. Patients graded the response according to his\her own observation of clinical improvement in percentage on VAS.

Side effects seen with both chemical agents during the peeling period and during follow-up were also inquired and recorded.


Data thus collected were analyzed using student's "t-test" for parametric data and "chi-square" for nonparametric data with statistical software Primer version 6.

### III. RESULTS

Out of 80 patients, 73 (36 in group A and 37 in group B) completed the study. Majority of the patients were in 18-25 years of age groups. Mean age in Group 'A' was  $21.00 \pm 2.37$  years in a Group 'B' was  $21.28 \pm 3.40$  years. There was a male preponderance, with the M:F ratio being 1.9:1. There was no statistically significant difference between these two study groups in term of age and sex wise distribution. There was no significant difference in duration of Acne and pre treatment scores between two groups thus confirming that the groups were comparable to begin with.

**Objective assessment** of treatment outcome, done by the researcher revealed the following-both the groups showed a constant decrease in the mean scar score (Quantitative global acne scar score) as compared to the pre-peel scores.(Figure 1.)

**Figure 1**  
Comparison of effects of Glycolic acid peels and Salicylic acid peels on total Acne Scar Score



In Group 'A', there was significant reduction in scar score ( $p < 0.05$ ) occurred after second peel onward and at the end of study, 15.54% reduction in pre peel score was observed. In Group 'B', significant reduction in score occurred after first peel onward and at the time of follow up 17.50% reduction in pre peel score with each peeling session which indicate the successive peeling may improve the scar further. Both of the chemical agents led to significant reduction in the total acne scar score but there was no significant difference was found between two groups. (Table 2)

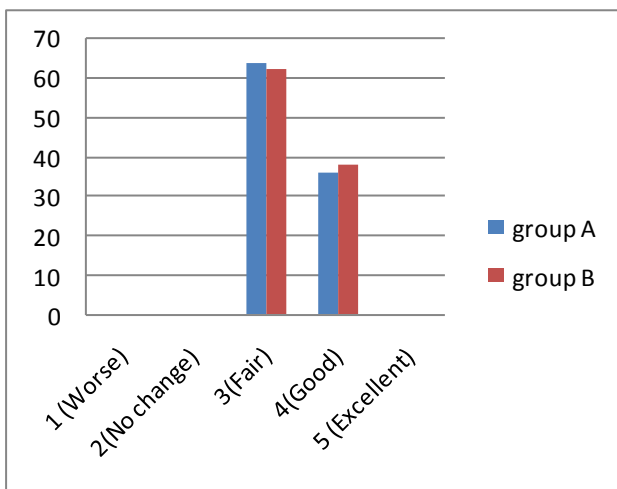
**Table 2**  
**Objective assessment of improvement in acne scar score in both the groups**

Peel	Group –A(n=36) GA peel				Group-B(n=37) SA peel				p-value Gp 'A' v/s Gp 'B'
	Mean	SD	Change over base line score	p-value of change	Mean	SD	Change over base line score	p-value of change	
Baseline	18.28	4.08			17.14	4.77			0.276
After 1st peel	18.14	3.98	0.14	0.134	17.00	4.86	0.14	0.023	0.277
% changes			0.76%				0.82%		
After 2nd peel	17.39	4.04	0.89	0.00	16.05	4.70	1.09	0.00	0.198
% change			4.87%				6.36%		
After 3rd peel	16.39	4.12	1.89	0.000	15.03	4.62	2.11	0.000	0.188
% changes			10.34%				12.31%		%
After 4th peel	15.44	4.16	2.84	0.000	14.14	4.29	3.00	0.000	0.190
% changes			15.54%				17.50%		

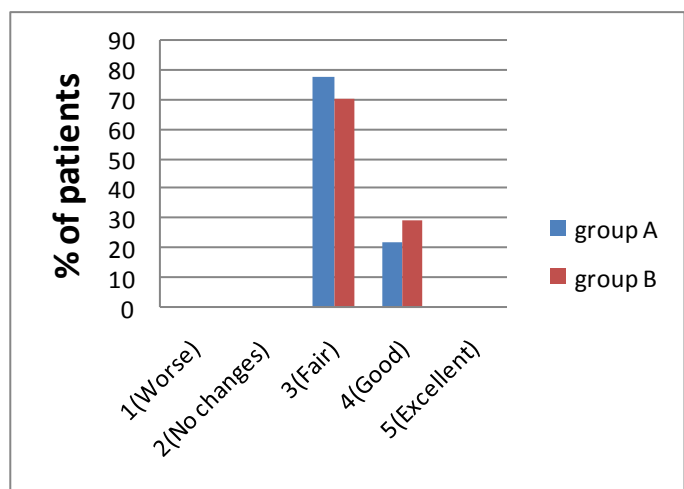
**S.D\* =standard deviation**

**Subjective Assessment at the end of study:** Visual analogue scale (VAS) score assessed by the patients, researcher and an independent observer. All the three subjective assessors found overall higher reduction of score for salicylic acid peels but the difference was not statistically significant. (Figure 2-4) None of the patients reported no change or worsening of pre peel status. It was also observed that both of the peeling agents had more action on mild and moderate scars in comparison to deeper severe scars


**Figure 2**  
**Comparison of VAS in both Groups**  
**(by patients at end of study)**



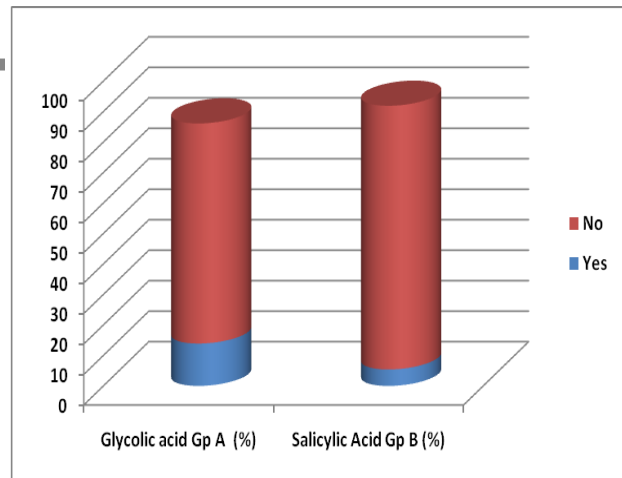
**Figure 3**  
**Comparison of VAS in both Groups**  
**(by Researcher at end of study)**



**Figure 4**  
**Comparison of VAS in both Groups**  
**(by Independent Observer at end of study)**



**Figure 5**  
**Comparison of Side Effects in both Groups**



**Side effects:** A large majority of patients (72.2% for Group 'A' and 86.5% for Group 'B') did not develop any side effect due to peeling with these chemicals. This difference was not found significant (Figure 5)

When type of side effects were observed it was found that 13.9% patients in Group 'A' and 5.4% patients in Group 'B' developed a burning or stinging sensation. Dryness was seen in 8.3% and 5.4% patients in group 'A' and group 'B' respectively. Post inflammatory hyper pigmentation was seen in 5.6% patients in group 'A' and 2.7% patients in group 'B'. This distribution of side effects between both the groups were not found with significant variation. (Table 3)

**Table 3**  
**Comparison of Type of Side effects in both groups**

S. No.	Side Effect	Group A (N=36)		Group B (N=37)		p Value
		No.	(%)	No.	(%)	
1	<b>Burning or Stinging Sensation</b>	5	(13.9)	2	(5.4)	0.405
2	<b>Dryness</b>	3	(8.3)	2	(5.4)	0.975
3	<b>Post inflammatory hyper pigmentation</b>	2	(5.6)	1	(2.7)	0.981

**Chi-square = 0.171 with 2 degrees of freedom; P = 0.918**

#### IV. DISCUSSION

Scarring is a well recognized sequel of acne. Scarring has been linked to poor self esteem, anxiety, altered social interaction, body image alterations, embarrassment anger, lowered academic performance. Because of the prevalence of acne scarring and strong negative emotions it endangers in affected patients, several approaches have been developed for its treatment, with varying success rates.

Chemical peeling is the process of applying chemicals to the skin to destroy the outer damaged layers and accelerate the repair process. Chemical peeling is used for the reversal of signs of skin ageing and for the treatment of skin lesions as well as scars, particularly acne scars. Dyschromias, wrinkles and acne scars are the major clinical indications for facial chemical peeling.<sup>5</sup>

Alpha hydroxy acids and beta hydroxy acids are the most commonly used peels. Glycolic acid peels, an alpha-hydroxy acid, act by thinning the stratum corneum, promoting epidermolysis and dispersing basal layer melanin. It increases dermal hyaluronic acid and collagen gene expression by increasing secretion of IL-6.<sup>6</sup>

Salicylic acid is one of the best peeling agents for the treatment of acne scars. It is a beta hydroxyl acid agent which removes intracellular lipids that are covalently linked to the cornified epitheloid cells. The most efficacious concentration for acne scars is 30% in multiple session, 3-5 times, every 3-4 weeks.<sup>7,8,9</sup>

There are only few studies using these agents for treatment of acne scars. Grime PE, in their study on safety and efficacy of salicylic acid peel in darker racial ethnic groups, studied 25 patients of various dermatosis of which 5 patients had post inflammatory hyperpigmentation. It was seen that salicylic acid peels expedited and facilitated resolution of post inflammatory hyperpigmentation. Significant improvement occurred in 5/5(100%) of patients.<sup>10</sup> Garg et al. in their study showed that percentage changes in icepick scars (week 0 to week 24) was 10.4% with glycolic acid peels and 13.2% with Salicylic-mandelic acid peels. The change in boxcar scars from baseline to end of study was 20.1% with GA peels and 23.3% with SMPs. There was no change in rolling scars with either of the two agents.<sup>11</sup> Erbagci Z et al. in their study compared the effect of peels with topical daily glycolic acid in the treatment of atrophic acne scars. The differences between the results in the different groups were statistically significant at week 24( $p < 0.001$ ).<sup>12</sup>

A study conducted by Sharad evaluated the use of glycolic peel as an adjuvant to micro needling in pigmented skin. Three months after the last treatment were performed, while both groups showed improvement of acne scars, the group that had received GA was significantly superior. This indicated that glycolic acid peeling had an additive effect to the micro needling in improving acne scars by promoting neocollagenesis.<sup>13</sup>

In present study, the result showed significant reduction in scar score after first peel onwards in group B whereas in group A, significant reduction occurred after 2<sup>nd</sup> peel. It suggest that salicylic acid is more effective and has rapid action in comparison to glycolic acid, although both of the agents led to significant improvement in total acne scar score at the end of study with no significant difference between two. Both of the peeling agent had more action on mild and moderate scars in comparison to deeper severe scars. It was observed that number of mild and superficial scars decreased, whereas some of moderate scars convert into mild scars. There was no visible improvement in severe scar like icepick scars, linear or troughed dermal scarring and deep, broad atrophic areas. Best response was seen in hyperpigmented macular scars which cleared almost completely. However, someone might argue that macular scars are self limiting, but it takes many months. In present study, with the use of chemical peels, macular scars disappeared or fade within weeks. So it is in concordance with previous studies that these peeling agents expedited and facilitated the resolution of post inflammatory hyperpigmentation.<sup>10</sup>

As both of peeling agents are superficial peels, they serve only to resurface the upper layer of the epidermis. Both stimulate the dermal fibroblast to deposit more collagen, elastin, and glycosaminoglycans in the papillary dermis. A more orderly and parallel arrangement of the fibers is also seen with both agents.<sup>14</sup> Thus, a gradual decrease in number of superficial scars and a decrease in the depth of deeper scars is observed.

As the icepick scars extend to deep dermis or subcutaneous tissue, it is beyond the reach of superficial peels used in our study. However, atrophic dish like scar and shallow boxcar scars being relatively superficial responded better than the other types of scars.

Although, at the end of study, mean visual analogue scale scores were higher for Salicylic acid in all three groups (patients, treating researcher and an independent observer), there was no statistically significant difference was noted between two agents. Subjective grading of response by the patients was higher in comparison of researcher and independent observer. It can be explained by the fact that along with decrease in acne scar, chemical peeling also rejuvenate the facial skin which increased the satisfaction level of patients. In addition to the improvement in scars, there was an improvement in skin texture and tone. Chemical peeling also led to the improvement in associated condition like active acne, pigmentary disorders( eg. Melasma, post inflammatory hyperpigmentation) and epidermal growths like milia. These finding are in concordance with result of previous studies which suggested the use of chemical peels for these indications.<sup>11, 15</sup>

Complication of superficial chemical peels which have been reported in literature include infections, dryness, persistent erythema, allergic reactions, post inflammatory hyperpigmentation, line of demarcation and scarring. Most of the adverse reactions (dryness, desquamation, burning sensation, post inflammatory hyperpigmentation) that occurred in present study were mild and were expected for such treatment.

In a study conducted by Garg et al., large majority(60.9% for Glycolic acid peel and 76.1% for Salicylic-mandelic acid peels) of patients did not develop any side effect due to peeling, 17.3% patients developed a burning or stinging sensation, and 8.7% of the GA peel group and none of SMP group had visible desquamation. Dryness was seen more often with SMPs(14.28%). Photosensitivity was seen in one patient each in each group.<sup>11</sup> In another study done by Grimes, side effects were absent in 84% of patients receiving SA peels. 4 of 25(16%) patients experienced mild side effects. 3 patients had transient dryness and hyperpigmentation which resolved within 7-14 days. Residual hypo or hyperpigmentation did not occur.<sup>10</sup> So observations of these studies were well in resonance with present study.

## V. CONCLUSION

Analyzing the result of this study, it was concluded that both 50% Glycolic acid and 30% Salicylic acid peels are safe and equally effective in the treatment of mild and moderate acne scarring. However Glycolic acid peels are associated with slight higher incidence of minor side effects, both type of peels offer good treatment option for post acne scars.

In comparison to newer machine based therapies for acne scars, chemical peeling is easy to apply, affordable and can be performed in outpatient department without any special requirements. As both the peeling agents turned out safe and efficacious, use of 50% glycolic and 30% salicylic peels as an adjuvant or as a 1st line therapy for mild to moderate atrophic acne scars is suggested.

## CONFLICT

None declared till date.



## REFERENCES

- [1] Leydon JJ. A review of the use of combination therapies for treatment of acne vulgaris. *J Am Acad Dermatol* 2003; 49:200-10
- [2] Layton AM, Henderson CA, Cunliffe WJ. A clinical evaluation of acne scarring and its incidence. *Clin Exp Dermatol* 1994;19:303-8.
- [3] Cunliffe WJ, Gould DJ. Prevalence of facial acne vulgaris in late adolescence and in adults. *Br Med* 1979;1:1109-10.
- [4] Goodman GJ, Baron JA. Post acne scarring: A quantitative global scarring grading system. *J Cosmet Dermatol* 2006;5(1):48-52
- [5] Douglas Fife. Practical Evaluation and Management of Atrophic Acne Scars. *J Clin Aesthet Dermatol* 2011;4(8):50-57.
- [6] Bernstein EF, Lee J, Brown DB. Glycolic acid treatment increases type 1 collagen mRNA and Hyaluronic acid content of human skin. *Dermatol Surg* 2001;27:429-33.
- [7] Lazo ND, Meine JG, Downing DT. Lipids are covalently attached to right corneocyte protein envelopes existing predominantly as B-sheet: a solid-state nuclear magnetic resonance study. *J Invest Dermatol* 1995;105(2):296-300.
- [8] Swinehart JM. Salicylic acid ointment peeling of the hands and forearms: effective nonsurgical removal of pigmented lesions and actinic damage. *J Dermatol Surg and Oncol* 1992;18(6):495-8.
- [9] Imayama S, Ueda S, Isoda M. Histologic changes in the skin of hairless mice following peeling with salicylic acid. *Archives of Dermatology* 2000;136(11):1390-95
- [10] Grimes PE. The safety and efficacy of salicylic acid chemical peels in darker racial ethnic groups. *Dermatol Surg* 1999;25:18-22.
- [11] Garg VK, Sinha S, Sarkar R. Glycolic acid peels versus Salicylic- Mandelic acid peels in active acne vulgaris and post acne scarring and hyperpigmentation: A comparative study. *J Dermatol Surg* 2009;35:59-65.
- [12] Erbagci Z, Akcali C. Biweekly serial glycolic acid peels vs. long term daily use of topical low strength glycolic acid treatment of atrophic acne scars. *Int J Dermatol* 2000;39:789-94
- [13] Sharad J. Combination of micro needling and glycolic acid peels for the treatment of acne scars in dark skin. *J Cosmet Dermatol* 2011;10:317-23.
- [14] Klingman D, Klingman AM. Salicylic acid as a peeling agent for the treatment of acne. *Cosmetic Dermatol* 1997;10:44-7.
- [15] Sarkar R, Kaur C, Bhalla M. The combination of glycolic acid peels with a topical regimen in the treatment of Melasma in dark skinned patients: A comparative study. *Dermatol Surg* 2002; 28: 828-32